

# Inferior alveolar and lingual nerves injury and repair: A literature review on microneurosurgery

Sittipong Chaimanakarn<sup>1</sup>, Pavitra Fooanant<sup>2</sup>, Basel Mahardawi<sup>3</sup>, Watus Sakdejayont<sup>4</sup>

<sup>1</sup> Oral & Maxillofacial Surgery Maha Chakri Sirindhorn Dental Hospital, Faculty of Dentistry, Mahidol University

<sup>2</sup> Phichai Hospital, Uttaradit, Thailand

<sup>3</sup> Oral Maxillofacial Surgery Department, Faculty of Dentistry, Mahidol University

<sup>4</sup> Oral Maxillofacial Surgery Department, Faculty of Dentistry, Mahidol University

Injury of the inferior alveolar and lingual nerves is one of the unexpected complications due to certain dental procedures that are proximate to the nerve, such as the removal of mandibular third molars, root canal treatment, implant placement, and the local anesthetic injection for the nerve block. Therefore, understanding the principles of nerve healing and the techniques of nerve repairing is essential in an attempt to reverse this occurrence. The purpose of this article is to provide an overview of the anatomy of nerves, physiology of injured nerve and its grading, as well as some of the general principles of peripheral nerve repair and nerve graft techniques

**Keywords:** Nerve injury, Neuroma, Neurolysis, Neurorrhaphy, Nerve grafting, Wallerian degeneration

**How to cite:** Chaimanakarn S, Fooanant P, Mahardawi B, Sakdejayont W. Inferior alveolar and lingual nerves injury and repair: A literature review on microneurosurgery. M Dent J 2019; 39: 41-52.

## Introduction

The trigeminal nerve, as well as its outlying branches, is vulnerable to be injured. This incidence can occur as a result of maxillofacial trauma, or iatrogenic reasons in the field of dentistry and medicine. [1] Symptoms resulted from nerve injuries diminish spontaneously in general, however, some patients need surgery. Signs for surgery may involve persistent anesthesia, dysesthesia, dense hypoesthesia, as well as any feeling of discomfort or pain. [2]

Knowledge of nerve anatomy, characteristics and pathophysiology of nerve injury, as well as the treatment options are necessary for maxillofacial surgeons to perform surgery without interfering with the nerve, and to be able to handle complications in case injury occurs.

## Neuroanatomy

The nerve fibers are one of the main components of the peripheral nerves. These are composed of the axons or neurites surrounded by the innermost loose collagenous sheath, named the endoneurium, which protects and nourish the axons or neurites. The endoneurium and the axons or neurites are attached with each other forming an accumulation of nerve fibers, called fascicles, and these, in turn, are enclosed by a thick connective tissue sheath of dense collagen fibers, called perineurium, which provide tensile strength to nerves. The fascicles with perineurium, which are embedded in loose connective tissue, are coiled with blood vessels and encircled by the connective tissue layer, called epineurium. The major function of epineurium is to nourish and protect the fascicles. [3, 4]

**Correspondence author:** Watus Sakdejayont

Department of Oral Maxillofacial Surgery, Faculty of Dentistry, Mahidol University,  
6 Yothi Road, Ratchathewi District Bangkok 10400 Thailand

Email: Watus.sak@mahidol.ac.th

Received : 1 October 2019

Accepted : 10 April 2019

There are three types of fascicular patterns in the peripheral nervous system. The monofascicular (one large fascicle), the oligofascicular (2–10 fascicles), and the polyfascicular (>10 fascicles). [5]

The fascicular pattern of the inferior alveolar nerve and the lingual nerve is polyfascicular which have abundant interfascicular connective tissue. Direct nerve trauma to the polyfascicular pattern has is rare because the needle would pass preferentially through the interfascicular spaces. In addition, the coaptation (realignment of fascicles) is difficult to perform due to the presence of many fascicles.

Both of the myelinated (one Schwann cell within the nerve fiber) and unmyelinated (one Schwann cell within a number of nerve fibers) nerves are surrounded by the Schwann cells which play an essential role in restoring and survival of nerve after injury. The myelin sheaths are responsible for nerve depolarization, repolarization, and conduction of a nerve impulse throughout the nerve fiber. [5]

The blood supply of peripheral nerves is mainly composed of a complex anastomotic network of blood vessels, forming two base arterial systems. The first lies superficially on the nerve and the second lies within the epineurium, in addition to a minor longitudinal system, which lies within the endoneurium and perineurium, and is linked by the anastomotic network. [4]

## Nerve injury

### Types of injury

The most common type of basic injury is **Stretch-related injury**. The collagenous endoneurium within the peripheral nerves are elastic, but injury can occur when traction forces exceed the stretch capacity of the nerve, however, the continuity remains. Another type is **Lacerations**, which is created by a sharp injury. The complete transection can be seen but more often the continuity still remains. **Compression** is a type of injury that may cause the loss of both sensory and motor function.

### Nerve injury classification

The grading of peripheral nerve injury, using patient's symptoms and microscopic change of nerve after injury, has been developed to help the clinician give a prognosis of the injury. The grading systems that are frequently used include Seddon classification and Sunderland classification. [6]

**Seddon classification** [4, 6, 7], it is clinically used more frequently than Sunderland's. This classification categorizes the injury into three broad types according to the severity of the injury. The mildest type is **Neurapraxia**, which is characterized by local myelin damage, usually secondarily to compression. The continuity of nerve remains but there is an incidence of a transient functional loss. There is little or no microscopic change. Therefore, the prognosis is good, and it may heal within weeks or months. **Axonotmesis** is defined as a complete interference of the axon and the enclosing myelinated sheath but the surrounding connective tissue, mainly the perineurium and epineurium, is not damaged. The common cause of this type is lacerations. Prognosis depends on the boundary of injury with a poorer outcome when the severity of injury is increased. The most severe injury is **Neurotmesis**, which is characterized by the discontinuity of the entire nerve. The main cause of this type is major trauma, resulting in a complete loss of function which cannot recover without surgery. Prognosis is poor even after undergoing a surgical procedure (Figure 1).

**Sunderland classification**. [4, 6] nerve injury is divided into five categories:

1. **Sunderland type 1 injury**, a first-degree injury, is the same as neurapraxia. This type can completely recover within weeks or months.
2. **Sunderland type 2 injury**, a second-degree injury, is the same as axonotmesis. The continuity of endoneurium, perineurium, and epineurium remains, while the axons are physiologically disrupted. The axons can regenerate and recover completely, as the endoneurium is still intact. Timing for recovery depends on the extent of injury, usually extends to several months.

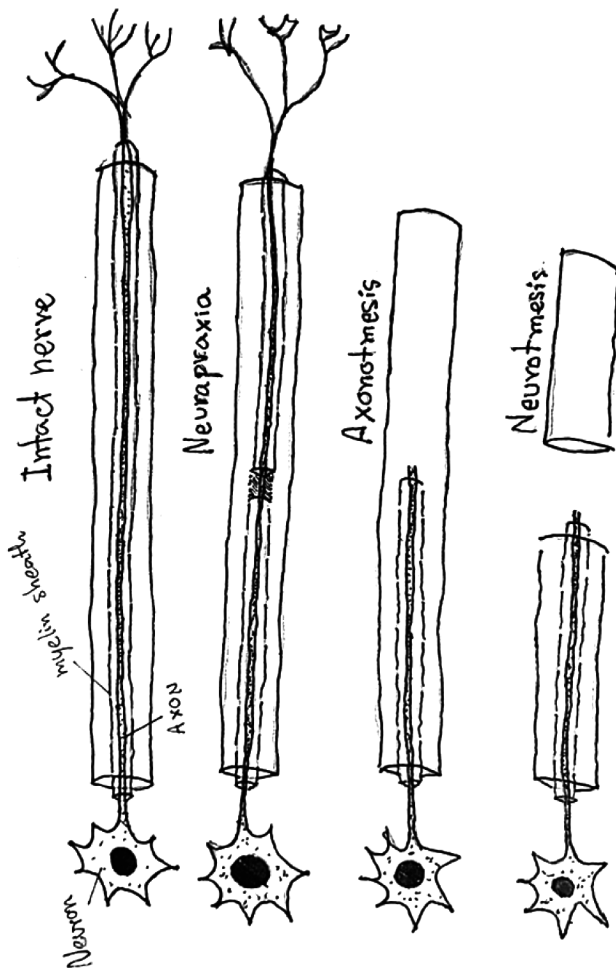


Figure 1 Intact nerve and types of nerve injury

3. **Sunderland type 3 injury**, the degree of severity is in between axonotmesis and neurotmesis. In this type, is the axons and parts of endoneurium are disrupted, while the perineurium and epineurium are intact. Functional recovery depends on the level of endoneurial damage, which may take place but may not be complete.

4. **Sunderland type 4 injury** Epineurium is intact but the other portions are discontinued. This type of injury demands surgical repair or reconstruction and allow only minimal recovery to occur.

5. **Sunderland type 5 injury**, most serious type of injury, as it is equivalent to neurotmesis. The nerve is completely disrupted and spontaneous recovery cannot take place.

#### Nerve response to injury

The functional recovery after axon injury may be complete if the continuity is maintained.

For instance, Neurapraxia caused by lingual nerve compression from the surgical removal of impacted third molar, has a good prognosis in relation to the functional recovery, and takes weeks or months. Axonotmesis is denervation in the distal segment of an axon, therefore, an uninjured part is maintained and there is a possibility for the axon to heal and innervate the target organ again. Neurotmesis has a complete functional loss and is not likely to recover. Moreover, the recovery of the nerve is age-related, consequently, adults have inferior functional recovery than children. [8]

After an injury, the basic processes of nerve healing involve degeneration and regeneration. In 1850, Waller [9, 10] described the degeneration in the distal division of nerve after the transection, as 'Wallerian degeneration'. In microscopic changes, the evidence of distal degeneration was seen. the phagocytes that were involved in myelin and cellular debris degradation were Schwann cells, hematogenous cells or monocytes, endogenous cells, and mesenchymal cells or fibroblasts. The degradation process continues until the axons are fully resorbed. Another theory presented by Waller is the 'outgrowth theory' which explains the regenerated neuron tissue from the proximal segment. Moreover, y Cajal [11] explained nerve regeneration from proximal segment. After the injury, the nucleus moves to the border of the body of the cell and undergoes neuronal chromatolysis. At a later stage, the cell volume increases due to the production of RNA. During 24 hours after injury, an axon regenerates into axonal sprouts and the tips of the sprouts produce axons along the neural tube at a velocity of 1 to 4 mm/day. In day four to twenty, the overall metabolism and RNA production increases. After that Schwann cells migrate, proliferate, and begin to form a new myelin "conduits", then they change into a nonmyelinated form, called '**bands of Bungner**' which influence the direction of sprouting.

If the proliferation is not successful, or the reparative processes fail to occur, it can form a **neuroma**. The failure of the reparative process

may result in scar formation, malalignment of nerve stump, or insufficient factor production. In surgical management, neuroma must be removed completely from proximal and distal stump before suturing, to improve the outcome of functional sensory recovery.

## Microneurosurgery

### Intervention of nerve

Microsurgery of peripheral nerve injury is done in the operation room under general anesthesia, using microsurgical instruments and sutures, after ensuring adequate magnification. The basic principle of trigeminal nerve microsurgery consists of exposure, hemostasis (achieved by hypotensive general anesthesia, locally applied hemostatic agent, as well as an electrocoagulation), visualization, scar tissue or any foreign body removal, nerve preparation, then moving to the suturing step which should be done without causing any tension to the nerve. Nerve grafting is preferable if the nerve cannot be sutured without tension. [1, 12, 13]

### Surgical procedure

#### 1. Neurolysis

Neurolysis is a procedure used for the decompression of the nerve which was affected by neuroma, fibrosis, or scar tissue. Initially, the examination of the site of lesion and external neurolysis are done by removing scar tissue surrounding the nerve. In some cases, the compression is eliminated and the function is restored by only external neurolysis. However, in some cases, external neurolysis alone is not adequate, and the scar tissue remains in the nerve, therefore internal neurolysis should be indicated. This procedure is done by removing the scar at the epineurium as a first step, which allows the surgeon to find out whether the scar tissue in the fascicles is present or if they are still intact. In case of any existence of a scar in the connective tissue, the nerve is split into a group of fascicles or kept as a fascicle, according to

each case, then the scar is removed. In order to save the blood supply, the healthy paraneurium is left intact. After neurolysis is done, the nerve is assured to be placed into healthy tissues, away from the scar bed, to avoid any scar reformation. Neurolysis is appropriate for the lingual nerve which is located in the floor of the mouth. In contrast, it cannot be performed with the inferior alveolar nerve when the lesion is in a bony canal. [3]

#### 2. Direct repair (neurorrhaphy)

When nerve injury occurs and microsurgery is required, the procedure of choice and has the best results is direct nerve repair. Three main techniques of direct nerve repair are as follows. [14]

##### 2.1 Perineural or fascicular repair [14, 15] :

In this technique, sutures are placed through perineurium for the repair of the individual fascicle, using 8-0 to 10-0 non-resorbable nylon (2 or 3 stitches for each fascicle) under high magnification. The interfascicular epineurium is stripped to increase the length of each fascicle. Dissecting out each fascicle and placing numerous sutures will lead to a time-consuming process and might cause fibrosis.

2.2 funicular repair [14, 15] : In this method, sutures are placed for aligning groups of fascicles, through the interfascicular epineurium, using 8-0 to 10-0 non-resorbable nylon. Minimal numbers of suture should be applied (2-3 stitches for each group) to avoid any scar formation. The group of fascicles is isolated by dissecting external epineurium. The advantage of this technique is preserving the anatomical arrangement of fascicle, therefore, the blood-nerve barrier is less likely to be damaged, scar formation is less, and the operation time is reduced.

##### 2.3 Epineural repair (commonly used) [14, 15] :

In this technique, sutures are made through the epineurium to align the nerve end. The principle is to protect the consistency of the injured nerve with tension-free and suitable alignment. A minimal number of sutures are required (4 to 8 stitches) using 8-0, 10-0 non-resorbable nylon. The epineural

repair is the technique of choice for the repair of the trigeminal nerve branch, as it is a non-grouped, polyfascicular pattern (different-sized fascicles).

### 3. Nerve grafting

This procedure is indicated when nerve injury or nerve preparation is shown to cause discontinuity defect accompanied by tension at the repair site. An additional indication is when the proximal stump of a nerve is gravely injured but distal stump can be salvaged. There are 4 types of donor nerve graft (1) **autogenous graft**; from a different site of the same recipient. (2) **isograft**; from genetically identical individuals, (3) **allograft**; from genetically non-identical individuals, (4) **xenograft**; from different species. [14]

The first key point of nerve grafting is that the proximal and distal stump should be set to receive the graft by removing neuroma in the nonfunctional and damaged portion. After confirming that the repair site is tension-free, the number of nerve grafts and the length is then measured. Normally, 10% longer than the measured gap is required for the graft to prevent any shrinkage or retraction. In the next step, the graft is placed between proximal and lateral stump applying two sutures (8-0 to 10-0 nylon). The sutures should be passed through the epineurium, interfascicular epineurium, and perineurium. The graft must be placed into a healthy, vascularized tissue to prevent scar formation and allow for appropriate nourishment of the graft. [15]

#### 3.1 Autogenous nerve grafts

The common autogenous donors for trigeminal nerve reconstruction are the great auricular and the sural nerves. The reason is that they are easy to harvest [14], in addition, the fascicular pattern and diameter of these nerves are appropriate for trigeminal nerve grafting. [16]

#### *Diameters of donor nerves [14]*

The diameters of the donor nerve graft should be suitable for the host nerve. The average diameter of the inferior alveolar nerve is 2.4 mm,

while it is 3.2 mm for the lingual nerve, and 2.1 mm for the sural nerve, with the least diameter for the great auricular nerve which is 1.5 mm. Size of the sural nerve is correlated with the inferior alveolar nerve by a cross-sectional diameter match.

#### *Length of Nerve Graft [14]*

The maximum harvest length, without difficulty, from the great auricular nerve is 2-4 cm and, sural nerve is 20-30 cm. Therefore the sural nerve might be the autogenous donor graft of choice because a larger graft than the great auricular nerve can be harvested.

#### *Patient Preference [14]*

Area of harvesting also depends on the area of numbness. Harvesting a graft from the sural nerve can cause insensibility of the lateral side of the foot and heel. Grafting from the great auricular nerve will lead to numbness in the ear, as well as the skin covering the posterior part of the mandible, and the lateral aspect of the neck. The incidence of a painful neuroma, which will necessitate additional treatment, is an additional risk of the donor site.

#### 3.2 Allograft nerve grafts

Allograft, a non-immunogenic and inert material, is an unlimited source of grafts with an advantage of not causing donor nerve morbidity. Processed allografts maintain the scaffold of nerve tissue. Axons regenerate to reach the host nerve and provide function via the conduits. [14]

#### 3.3 Entubulation repair

#### *Permanent conduit materials [17]*

A permanent conduit material for nerve graft is silicone. This graft might cause localized compression if long-term tubulation remains, which leads the axonal conduction to decrease, although a number of nerve fibers and axon size is sustained. Therefore, the silicone must be removed to achieve a better outcome. Another permanent nerve graft conduit is Gore-Tex vein grafts. Gore-Tex (polytetrafluorethylene) also has the same unfavorable outcomes as silicone. Previous studies recommended that Gore-Tex is

not proper for inferior alveolar and lingual nerve repair.

#### *Synthetic resorbable conduits [17]*

A bioresorbable material which is currently used as a mesh form to wrap internal organs and as a suture material is composed of polyglycolic acid. They are usually resorbed within 90 days by hydrolysis. In 1999, polyglycolic acid was developed into a conduit for nerve grafting as Neurotube (Neurogen). The internal diameter and length of Neurotube are 2 mm and 4 cm. Permanent tubing problems, compression, and demyelination, are terminated because the polyglycolic acid conduit can be resorbed. The advantages of this conduit have minimized the problems associated with the morbidity of the donor nerve. Neurotube conduit has a good preliminary result for inferior alveolar and lingual nerve grafting.

The graft conduit is prepared at least 1 cm longer than the gap from proximal to the distal stump. Suture through the conduit is done by using 8-0 to 10-0 nylon. The suturing technique is the mattress. [17]

#### 4. End-to-side neurorrhaphy

End-to-side neurorrhaphy connects the side of nearby donor nerve and the distal end of an injured nerve without alteration of the donor by direct repair. [18] Many surgeons create the **epineural window** at the side of the donor nerve before suturing, considering that the damaged nerve would enhance the sprouting of the axon. Viterbo et al. [19] stated that the end to side neurorrhaphy with or without epineural window has similar results in axonal regeneration. Other studies reported that an epineural window followed by suturing without injury to nearby perineurium improves the result of the end to side neurorrhaphy. In fact, nerve regeneration, trying to minimize damage to the donor nerve, will lead to better results. Sources of regenerating axon are still a controversy, however, they are mainly (1) collateral (nodal) sprouting from the neurorrhaphy site, (2) donor axon, (3) invasion

from the proximal stump of the injured nerve. [18]

The indication of this technique is to repair or regain the function of the injured nerve in which proximal stump is not available. The concept is the axonal sprouting from the nearby donor nerve to the distal stump of injured nerve by suturing or connecting them together. [20]

### Factors affecting nerve graft success [14]

#### *Time since the Injury*

Microsurgery repair of peripheral nerve injury with or without grafting should be done as immediate as possible after the damage to prevent atrophy, Wallerian degeneration, or any incidence of fibrosis in the lateral aspect of the nerve. Poor outcomes can occur if the repair was done 3, 6, 9, or 12 months or after a longer period since the injury happened. Wietholter et al. [21] reported that the best result for inferior alveolar and lingual nerve repair is within 3 weeks after nerve damage takes place. It is important to mention that some injuries have a better outcome after nerve repair, as the case of a lesser trauma to the nerve, or if a smaller size of the nerve graft is needed, or when it is possible to repair without the placement of a graft.

#### *Tension on Repaired Nerve*

Tension-free repair is an important requirement for microsurgery of the nerve. Graft length should be determined before harvesting by preparation of host nerve and checking the required size of the graft. The length can be shrunk approximately 20% during the healing phase. Consequently, the harvested nerve graft should be larger than the present nerve defect.

#### *Age of patient and other health factors*

Young patients usually have better outcomes than elderly patients, because of the better metabolic rates and healing, as well as the higher ability of adaptation to altered nerve programming and regeneration of the nerve. Moreover, in the elderly, there might be some systemic diseases that can adversely affect the outcome.

## Discussion

Since 1995 to 2017, there were several studies reported the factors associated with functional sensory recovery and the interval to achieve functional sensory recovery after microneurosurgery. These studies explained that the success of nerve repair depends on many factors such as patient's age, the interval from injury to repair, chief complaint (pain included in the 'chief complaint'), the difference in methods of repair, and the length of nerve gap or nerve graft. The interval to achieve functional sensory recovery varies among those studies.

Joshi and Rood [22] studied the efficacy of external neurolysis in cases with clinical symptoms related to lingual nerve 'entrapment'. Seven of the 10 patients showed significant improvement 12 months postoperatively and the rest did not have any benefit. Smith and Robinson [23] studied the level of sensory recovery in lingual nerve repair by epineural suture. They reported that the median patients' subjective assessment was 7 (0-10). Ten of 13 patients detected some stimuli, 13 of 13 patients detected pinprick, 10 of 13 patients had a decrease in two-point discrimination thresholds, and 6 of 13 patients returned to taste sensation.

Taking the timing of the surgical procedure into account, it is noticeable that earlier treatment leads to a better outcome. Hillerup and Stoltze [24] assessed the correlation between the timing of surgery for lingual nerve repair and the functional sensory recovery and demonstrated that median times to achieve functional sensory recovery for the early repair were 117 days and late repair were 249 days. Hillerup and Stoltze [24] stated that the rate of lingual nerve recovery after microsurgical repair was improved during the first 6 months after surgery, thereafter it was declined. Susarla et al. [25] assessed the correlation between the timing of surgery for lingual nerve repair and the functional sensory recovery, and demonstrated that median times to achieve functional sensory recovery for

the early repair were 117 days and late repair were 249 days. Rutner, Ziccardi and Janal [26] also reported the success rate of external, combined with internal neurolysis, neuroma excision, and direct repair or neuroorrhaphy in lingual nerve. The results of this study demonstrated that 18 of 20 patients (90%) had some neurosensory function improvement. Two patients (10%) expressed no neurosensory function improvement. One of these 2 patients had a delayed treatment, therefore, it might be an essential factor for not having a positive outcome. Fagin et al. [27] declared in their study that age, time from injury to repair, chief complaint (pain), and the difference in methods of repair were statistically significant factors associated to achieve functional sensory recovery after microsurgical nerve repair. Bagheri et al [28] also stated that those same factors affect the functional sensory recovery after nerve repair, but did not include "pain" in their chief complaint factor. Therefore, age also should be considered when performing microneurosurgery, as it can be involved in terms of the healing process, with younger age responding better than old age according to the literature.

Moreover, the method of nerve repair may have an impact on the treatment outcome in some cases. Yampolsky, Ziccardi and Chuang [29] indicated that acellular processed nerve allografts are a replacement to autogenous nerve graft. Their results showed 15 out of 16 patients who achieved functional sensory recovery in a mean time of 208 days. The function of allograft is a platform for nerve regeneration. In animal studies, processed nerve allograft and autograft have the same pattern of axonal regeneration. [30] Avance processed nerve allograft (AxoGenInc, Alachua, FL, USA), a human decellularized allograft product, is an alternative allograft for inferior alveolar and lingual nerves repair. In 2015, Zuniga [31] described the outcome of using Avance nerve graft to reconstruction inferior alveolar and lingual nerve in 21 nerve injuries. The total sensory function

improvement was 87%, in which the neurosensory score was; normal in 52% of the cases, mild impairment in 9%, moderate impairment in 26%, and severe impairment in 13% of them. There was no complete impairment. Furthermore, the results of immediate allograft for the use of long-span damaged portions of inferior alveolar nerve were demonstrated by Salomon, Miloro, and Kolokythas [32] in a retrospective study of 7 patients who resected mandibular pathology. 85.7% returned to some tactile sensation and superficial pain without over-response, 14.3% had good stimulation localization, and 14.3% of the patients had no sensory recovery.

In 2016, Wilson, Chuang and Ziccardi [33] reported the result of comparing type I collagen conduit (NeuraGen) with a porcine small intestinal submucosa conduit (AxoGuard), used for lingual nerve repair under microsurgery. Their result showed no statistically significant differences in functional sensory recovery between the 2 conduits.

In addition, it is important to mention that recovery or improvement may not take place after microneurosurgery in every case. Pogrel [34] evaluated the management of 51 patients who showed symptoms of inferior alveolar and lingual nerve injuries with indications for microneurosurgery. The results showed that 10 of 51 patients (19.6%) had good improvement, 18 patients (35.29%) had some improvement, and 22 patients (43.14%) had no improvement, indicating more than 50% of patients with improvement in sensation. Another study by Lam et al. [35] showed that in more than half of the cases, patients assessed their general satisfaction with inferior alveolar and lingual nerve repair to be good to excellent. Strauss, Ziccardi and Janal [36] also demonstrated the success rate

of the external combine with internal neurolysis, neuroma excision, and direct repair or neurorrhaphy in inferior alveolar nerve. Their results indicated 26 out of 28 patients (92.9%) who had neurosensory improvement. Two patients (7.1%) reported no improvement. All results from the previously mentioned studies, whether age, the method of nerve repair, and the interval between injury and repair were significant according to them, are summarized in Table 1.

## Conclusion

Out of these points, and the mentioned studies, as well as the previously shown table, we conclude that microneurosurgery is a viable option in an attempt to recover the nerve and to gain sensation, in cases if no spontaneous healing has taken a place. However, patients should be informed that this procedure does not guarantee a full nerve recovery. Several factors are important to consider when making decision to perform this surgery, namely, patient age and time after nerve injury with a possible effect of the method of nerve repair. Younger age and a less interval between the injury and treatment are crucial factors in achieving a good outcome.

## Acknowledgement

Department of oral and maxillofacial surgery,  
Faculty of dentistry, Mahidol university

**Funding:** None

**Competing interests:** None

**Ethical Approval:** Not required



**Table 1** Effect of age, method of nerve repair, and intervals from injury to repair. In addition to some of the main points regarding the healing according to some of the studies in the literature

Study	Interval from injury to repair	Result	Age effect?	Interval effect?	Method of repair effect?
Robinson and Smith [23] (1996)	(16 months)	Greatest number of patients underwent notable and valuable recovery after late lingual nerve repair	N/A	Yes	Yes
Pogrel [34] (2002)	(4 days - 9 months)	Earlier surgery (before 10 weeks) showed to be better than late procedures (after 10 weeks)	N/A	Yes	N/A
Joshi and Rood [22] (2002)	(13.5 months)	External neurolysis is preferable with patients who have symptoms of altered sensation in the along the lingual nerve	N/A	N/A	Yes
Lam et al. [35] (2003)	(6.8 months)	Group A (good to excellent) were younger, received direct suture mending, shorter nerve breaches, and less interval between injury and repair than group B (fair to poor), however, this was not statistically significant	Yes	Yes	Yes
Rutner, Ziccardi and Janal [26] (2005)	(8 months)	Time from injury until repair did not show any significant relation with the final outcome	N/A	No	N/A
Strauss, Ziccardi and Janal [36] (2006)	(6.6 months)	shorter times to surgery did not lead to significant Sensory improvement	N/A	No	N/A
Susarla et al.[25] (2007)	(E: 73.5 days L: 140 days)	Early intervention, neuroma formation, and type of repair were related to the time to FSR* (Early repair = <90 days, Late repair = >90 days)	N/A	Yes	Yes
Hillerup and Stoltze [24] (2007)	(12 months)	- Delay of repair showed a small but significant effect on the recovery of neurosensory function - Sensation recovery is associated with the type of the procedure	No	Yes	Yes
Yampolsky, Ziccardi and Chuang [29] (2017)	<b>(272 ± 249 days)</b>	The sole patient without FSR had presented preoperatively with hyperesthesia and neuropathic pain	N/A	N/A	Yes
Zuniga [31] (2015)	<b>(immediate)</b>	- Age did not show any statistically significant influence on the results but younger age might accelerate FSR - There was no influence of PNA size on the results at 1 year	Yes	N/A	N/A
Fagin et al. [27] (2012)	<b>(151.6 days)</b>	Age, time from injury to repair, presenting chief complaint (pain) , and method of repair were significantly associated with FSR (younger subjects seemed to have more chances to reach FSR)	Yes	Yes	Yes
Wilson, Chuang and Ziccardi [33] (2017)	(5.70 months)	no statistically difference was found regarding FSR among type 1 collagen conduit (NeuraGen) and porcine small intestinal submucosa conduit (AxoGuard)	N/A	N/A	No

\*FSR : Functional sensory recovery

## References

1. Ziccardi VB. Microsurgical techniques for repair of the inferior alveolar and lingual nerves. *Atlas Oral Maxillofac Surg Clin North Am* 2011; 19: 79-90.
2. Pogrel M, Kaban L. Injuries to the inferior alveolar and lingual nerves. *J Calif Dent Assoc* 1993; 21(1): 50-4.
3. Hausamen J-E, Schmelzeisen R. Current principles in microsurgical nerve repair. *Br J Oral Maxillofac Surg* 1996; 34: 143-57.
4. Lee SK, Wolfe SW. Peripheral nerve injury and repair. *J Am Acad Orthop Surg* 2000; 8(4): 243-52.
5. Miloro M. Microneurosurgery. In: Miloro M, Ghali G, Larsen PE, Waite PD, editors. *Peterson's principles of oral and maxillofacial surgery*. 2nd ed. London: BC Decker Inc; 2004: 822-3.
6. Burnett MG, Zager EL. Pathophysiology of peripheral nerve injury: a brief review. *Neurosurg Focus* 2004; 16: 1-7.
7. Osburne A. Peripheral nerve injury and repair. *Tsmj* 2007; 8: 29-33.
8. Maggi SP, Lowe JB, Mackinnon SE. Pathophysiology of nerve injury. *Clin Plast Surg* 2003; 30: 109-26.
9. Waller A. Experiments on the section of the glossopharyngeal and hypoglossal nerves of the frog, and observations of the alterations produced thereby in the structure of their primitive fibres. *Philos Trans R Soc Lond* 1850; 140: 423-9.
10. Stoll G, Griffin J, Li CY, Trapp B. Wallerian degeneration in the peripheral nervous system: participation of both Schwann cells and macrophages in myelin degradation. *J Neurocytol* 1989; 18: 671-83.
11. y Cajal SR. Mecanismo de la degeneracion y regeneracion de nervos. *Trab Lab Invest Biol* 1905; 9: 119.
12. Mackinnon SE, Colbert SH. Principles and techniques of peripheral nerve repair, grafts, and transfers. In: Thorne CH, Gurtner GC, Chung KC, Gosain AK, Mehrara BJ, Rubin JP, et al., editors. *Grabb And Smith's Plastic Surgery*. 7th ed. Philadelphia: Lippincott Williams & Wilkins (LWW); 2013: 82.
13. Meyer RA, Bagheri SC. Microsurgical reconstruction of the trigeminal nerve. *Oral Maxillofac Surg Clin North Am* 2013; 25: 287-302.
14. Wolford LM, Rodrigues DB. Autogenous grafts/allografts/conduits for bridging peripheral trigeminal nerve gaps. *Atlas Oral Maxillofac Surg Clin North Am* 2011; 19: 91-107.
15. Matsuyama T, Mackay M, Midha R. Peripheral nerve repair and grafting techniques: a review. *Neurol Med Chir (Tokyo)* 2000; 40: 187-99.
16. Miloro M, Ruckman III P, Kolokythas A. Lingual nerve repair: To graft or not to graft? *J Oral Maxillofac Surg* 2015; 73: 1844-50.
17. Wolford LM, Stevao EL. Considerations in nerve repair. *Baylor University Medical Center Proceedings* 2003; 16: 152-6.
18. Dvali L, Mackinnon S. Nerve repair, grafting, and nerve transfers. *Clin Plast Surg* 2003; 30: 203-21.
19. Viterbo F, Trindade JC, Hoshino K, Mazzoni AN. Latero-terminal neuroorrhaphy without removal of the epineural sheath. Experimental study in rats. *Sao Paulo Med J* 1992; 110: 267-75.
20. Tos P, Colzani G, Ciclamini D, Pugliese P, Artiano S. Clinical applications of end-to-side neuroorrhaphy: an update. *Biomed Res Int* 2014; 2014.
21. Wiethölder H, Riediger D, Ehrenfeld M, Cornelius C. Results of microsurgery of sensory peripheral branches of the mandibular nerve. *Fortschr Kiefer Gesichtschir* 1990; 35: 128.
22. Joshi A, Rood J. External neurolysis of the lingual nerve. *Int J Oral Maxillofac Surg* 2002; 31: 40-3.
23. Robinson P, Smith K. A study on the efficacy of late lingual nerve repair. *Br J Oral Maxillofac Surg* 1996; 34: 96-103.
24. Hillerup S, Stoltze K. Lingual nerve injury: II. Observations on sensory recovery after micro-neurosurgical reconstruction. *Int J Oral Maxillofac Surg* 2007; 36: 1139-45.
25. Susarla SM, Kaban LB, Donoff RB, Dodson TB. Does early repair of lingual nerve injuries improve functional sensory recovery? *J Oral Maxillofac Surg* 2007; 65: 1070-6.
26. Rutner TW, Ziccardi VB, Janal MN. Long-term outcome assessment for lingual nerve microsurgery. *J Oral Maxillofac Surg* 2005; 63: 1145-9.
27. Fagin AP, Susarla SM, Donoff RB, Kaban LB, Dodson TB. What factors are associated with functional sensory recovery following lingual nerve repair? *J Oral Maxillofac Surg* 2012; 70: 2907-15.
28. Bagheri SC, Meyer RA, Cho SH, Thoppay J, Khan HA, Steed MB. Microsurgical repair of the inferior alveolar nerve: success rate and factors that adversely affect outcome. *J Oral Maxillofac Surg* 2012; 70: 1978-90.

29. Yampolsky A, Ziccardi V, Chuang S-K. Efficacy of acellular nerve allografts in trigeminal nerve reconstruction. *J Oral Maxillofac Surg* 2017; 75: 2230-4.
30. Johnson PJ, Newton P, Hunter DA, Mackinnon SE. Nerve endoneurial microstructure facilitates uniform distribution of regenerative fibers: a post hoc comparison of midgraft nerve fiber densities. *J Reconstr Microsurg* 2011; 27: 083-90.
31. Zuniga JR. Sensory outcomes after reconstruction of lingual and inferior alveolar nerve discontinuities using processed nerve allograft—a case series. *J Oral Maxillofac Surg* 2015; 73: 734-44.
32. Salomon D, Miloro M, Kolokythas A. Outcomes of immediate allograft reconstruction of long-span defects of the inferior alveolar nerve. *J Oral Maxillofac Surg* 2016; 74: 2507-14.
33. Wilson MT, Chuang S-K, Ziccardi VB. Lingual nerve microsurgery outcomes using 2 different conduits: A retrospective cohort study. *J Oral Maxillofac Surg* 2017; 75: 609-15.
34. Pogrel MA. The results of microneurosurgery of the inferior alveolar and lingual nerve. *J Oral Maxillofac Surg* 2002; 60: 485-9.
35. Lam NP, Donoff RB, Kaban LB, Dodson TB. Patient satisfaction after trigeminal nerve repair. *Oral Surg Oral Med Oral Pathol Oral Radiol Endod* 2003; 95: 538-43.
36. Strauss ER, Ziccardi VB, Janal MN. Outcome assessment of inferior alveolar nerve microsurgery: a retrospective review. *J Oral Maxillofac Surg* 2006; 64: 1767-70.

