



Does the efficacy of direct inferior alveolar nerve block depend on patient position?

Watus Sakdejayont¹, Prued Chewpreecha¹, Kiatanant Boonsiriseth¹,
Binito Shrestha², Natthamet Wongsirichat¹

¹ Department of Oral and Maxillofacial Surgery, Faculty of Dentistry, Mahidol University, Bangkok, Thailand.

² Department of Oral and Maxillofacial Prosthodontic, Faculty of Dentistry Mahidol University, Bangkok, Thailand.

Abstract

Background: Inferior alveolar nerve block (IANB) is the most commonly employed technique to attain anesthesia of the mandible. Failure in IANB may be caused due to several factor, a factor may be the patient position. This study has to evaluate the effects of patient position on the efficacy of anesthesia from inferior alveolar nerve block (IANB) for lower third molar surgery.

Material and methods: This study was a double-blind prospective study, which comprised of 29 patients with an age range of 18-25 years. The patients were seated in a randomized position, up-right or supine position for each side, during the IANB. The level of anesthesia was measured by evaluating onset, duration, and profoundness of anesthesia, and the level of pain was assessed by Heft-Parker VAS.

Results: There were no statistically significant differences in the profoundness, subjective onset, objective onset, and duration of the anesthesia, and the level of pain during injection and surgery for the up-right and supine positions. The addition of local anesthetics for up-right and supine positions was 62.07 % and 55.17%, respectively. The results of the pain assessment showed 3.5 ± 1.7 during injection for the up-right position and 3.6 ± 1.7 for the supine position, and during surgery it was 2.9 ± 2.2 for the up-right position and 2.9 ± 2.1 for the supine position.

Conclusion: Patient position had no effect on the efficacy of anesthesia of the IANB by direct technique.

Keywords: patient position, inferior alveolar nerve block, anesthesia, articaine, lower third molar surgery

How to cite: Sakdejayont W, Chewpreecha P, Boonsiriseth K, Shrestha B, Wongsirichat N. Does the efficacy of direct inferior alveolar nerve block depend on patient position?. *M Dent J* 2016; 36: 175-181.

Corresponding author:

Natthamet Wongsirichat
Department of Oral Maxillofacial Surgery,
Faculty of Dentistry Mahidol University,
6 Yothi Street, Rachathewee District,
Bangkok 10400, Thailand
Email: natthamet.won@mahidol.ac.th
Tel: 022007777 ext 3333
Mobile phone: +66819095625

Received: 14 March 2016

Accepted: 26 April 2016

Introduction

Local anesthesia is most frequently used in dentistry for oral surgeries and routine dental procedures. Inferior alveolar nerve block (IANB) is the most commonly employed technique to attain anesthesia of the mandible. However, Kaufman (1984)¹ and Palti et al. (2011)² have reported high failure rates of IANB and pulpal anesthesia. Failure in IANB may be caused due to several factors, such as the inefficient technique, anatomical variations, etc. Several alternatives to the IANB, namely Akinosi, Gow-Gates techniques, etc., are available to the clinicians that can be performed following failure of IANB.³ However the clinicians should be skillful to carry out these procedures with confidence.^{4,5}

Goldberg et al.⁶ studied the degree of pulpal anesthesia obtained with the conventional inferior alveolar, Gow-Gates, and Vazirani-Akinosi techniques. In 2011, Zanette et al.⁷ studied two regional anesthesia techniques performed by inexperienced operators, and found that there were no significant differences in success rate of anesthesia. The use of different lengths and gauge of the syringe may also affect the success rate of anesthesia. To prevent failure due to anatomical variations, profound knowledge of anatomical structures and nerve locations is required. Palti et al.² also reported that achieving an effective anesthesia of the inferior alveolar nerve is one of the most difficult tasks for inexperienced dental practitioners. The main problem is the correct localization of the nerve in the region of the mandibular foramen. Accordingly, greater density of the mandibular alveolar bone, requirement for deeper needle penetration into the soft tissues, and limited access can also influence the success rate.

Many previous studies⁸⁻¹⁰ have focused on enhancing anesthesia success rates. However, there is no study regarding the efficacy of IANB by direct injection technique related to

the patient's position. Therefore, the purpose of this study was to evaluate the effects of patient position (up-right & supine position) on the efficacy of anesthesia of IANB by direct technique.

Materials and methods

Twenty-nine patients participated in this study.

The inclusion criteria select the patients were as follows:

- The age between 18-65, in good health.
- Not taking any medication that could alter pain perception.
- Had bilaterally symmetrical lower third molars¹¹ with a treatment plan of their surgical removal.
- The mandible was devoid of other pathologic lesions.

Exclusion criteria select the patients were as follows:

- Younger than 18 or more than 65 years of age.
- History of allergic to local anesthetics or sulfites.
- Pregnant.
- History of significant medical conditions that might affect anesthetic assessment.
- Active pathology at the injection sites.
- Inability to give informed consent.

Using a split mouth design, the patients were seated in a randomized position (up-right or supine position) and were injected with a local anesthetic solution, 1.7 mL of 4% articaine with 1:100,000 epinephrine, using the standard technique for IANB.¹² Before IANB injection at both sides, the soft tissue was tested at the distobuccal area of lower canine at the injected side using an intraoral *pain assessment device* (figure 1) and the mandibular canines were tested with an electric pulp tester (EPT) to ensure tooth vitality and to obtain the baseline values. Each patient was instructed to rate the

pain for each phase of the injection: needle insertion and during the surgery, using a Heft-Parker visual analogue scale (VAS). For the upright position, the patient was instructed to open their mouth and the mandibular occlusal plane was set parallel to horizontal plane (Figure 2). For the supine position, the patient's mandibular occlusal plane was set perpendicularly to the horizontal plane (Figure 3).

The inferior alveolar nerve block was carried out with a direct technique using a local anesthetic solution that comprised of

4% articaine with 1:100,000 epinephrine. The insertion point of the needle was centered 1 cm above the mandibular occlusal plane. The syringe was approached from the opposite side of the mouth over the contralateral premolars (Figure 4). The mandibular tissue was pierced on the medial border of the mandibular ramus within the pterygomandibular space until the medial surface of the alveolar bone was contacted while being lateral to the pterygomandibular fold and the sphenomandibular ligament. Following which, the injection was given.



Figure 1 The intraoral pain assessment device for testing soft tissue numbness

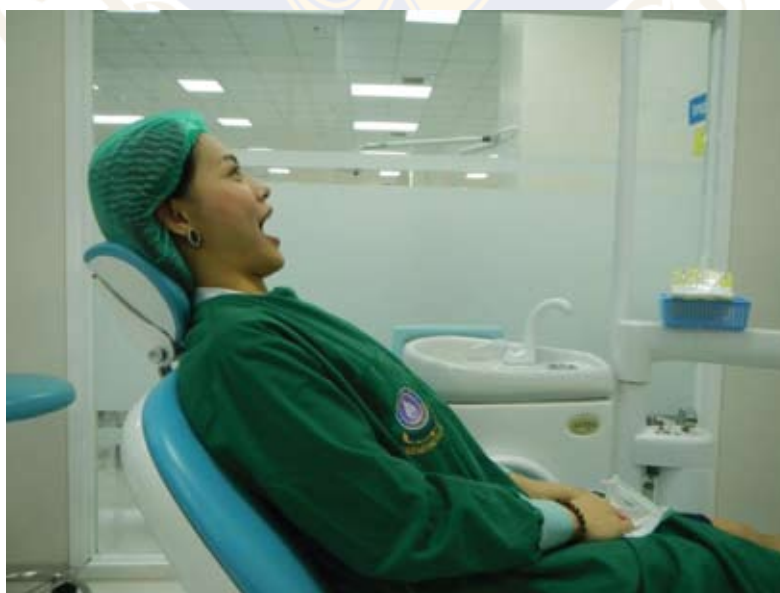

Figure 2 Patient in up-right position

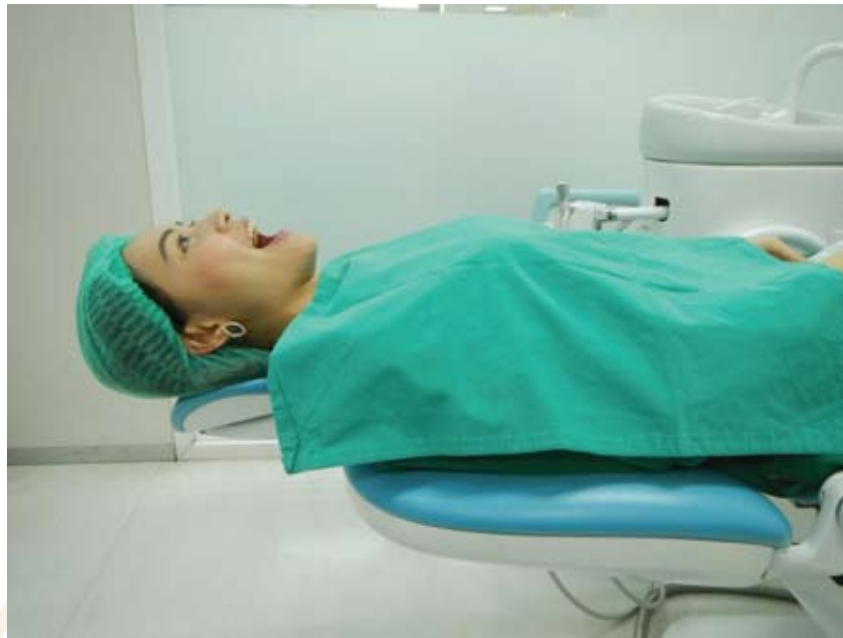
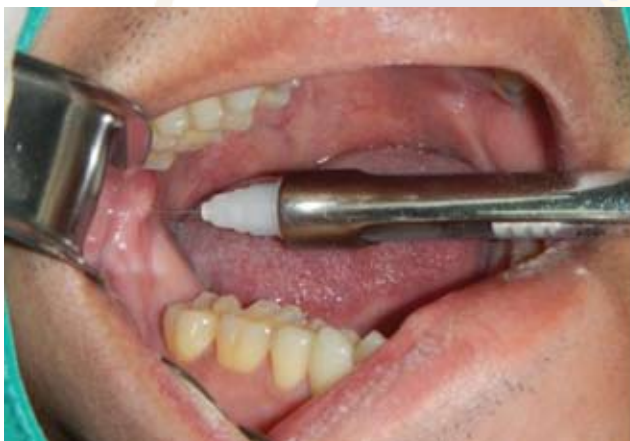
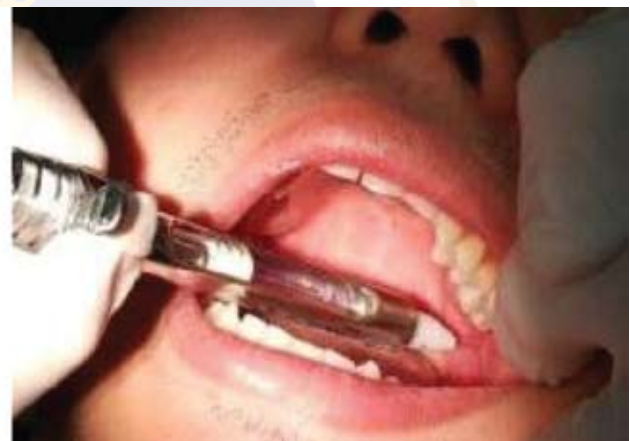Figure 3 Patient in supine position



Right side of the patient on the upright position



Left side of the patient on supine position

Figure 4 Patient being injected with the inferior alveolar nerve block

All patients were asked for the subjective onset of anesthesia as indicated by the numbness of the lips. Then the numbness of soft tissue was tested at the distobuccal area of lower canine at the injected side using an intraoral *pain assessment device* at the gingival sulcus (Figure 1). The testing continued in 1-minute cycles. When the soft tissue was completely numbed, the mandibular canines were tested twice with an EPT every minute for the objective onset. After the anesthesia of the pulp was attained, the patients were asked

to complete the VAS as before.

All the patients were injected at the right side of mandible with random position: up-right or supine. After the experiment as previously described was completed, the left side of mandible was also injected but with the patient in the another position. When the experiments were completed on both sides, the surgical removal of the third molar was initiated. The patients were asked to report the duration of anesthesia by a phone call, when the numbness disappeared.

Results

The age range of 29 patients (11 males and 18 females), who participated in this study, was 18-25 years with an average age of 21.

Figure 5 showed the mean of the subjective onset of anesthesia, according to the patient positions. No significant difference was noted between the up-right and supine positions (P-value 0.213). There was also no significant

difference between the two positions on the objective onset of anesthesia (P-value 0.858). Similarly, no statistically significant difference was noted in the duration of anesthesia between the two patient positions (P-value 0.632).

Figure 6 showed the results of pain assessment as interpreted via the VAS. Pain assessment during injection was 3.5 ± 1.7 for the up-right position and 3.6 ± 1.7 for the

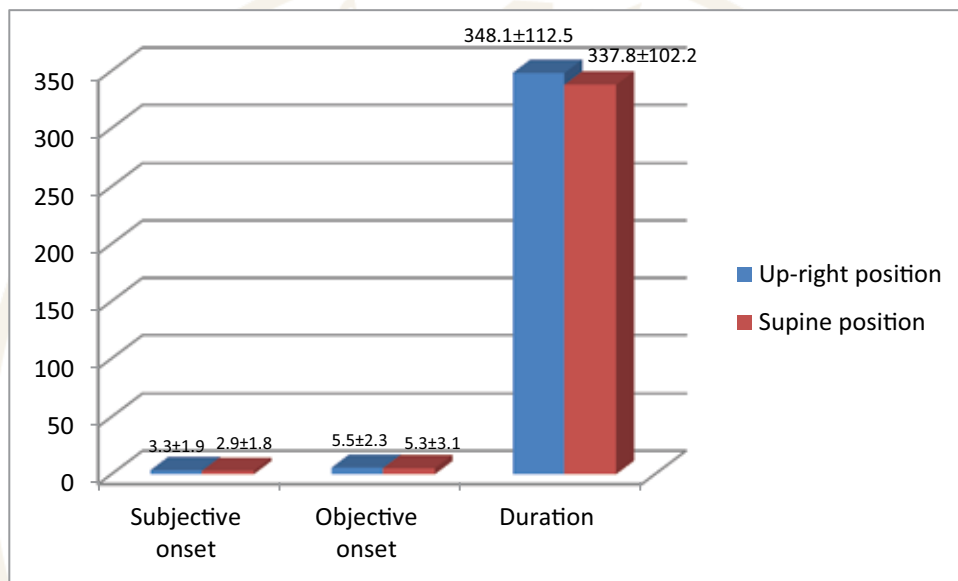


Figure 5 Means of subjective onset, objective onset, and duration of anesthesia categorized according to the patient position

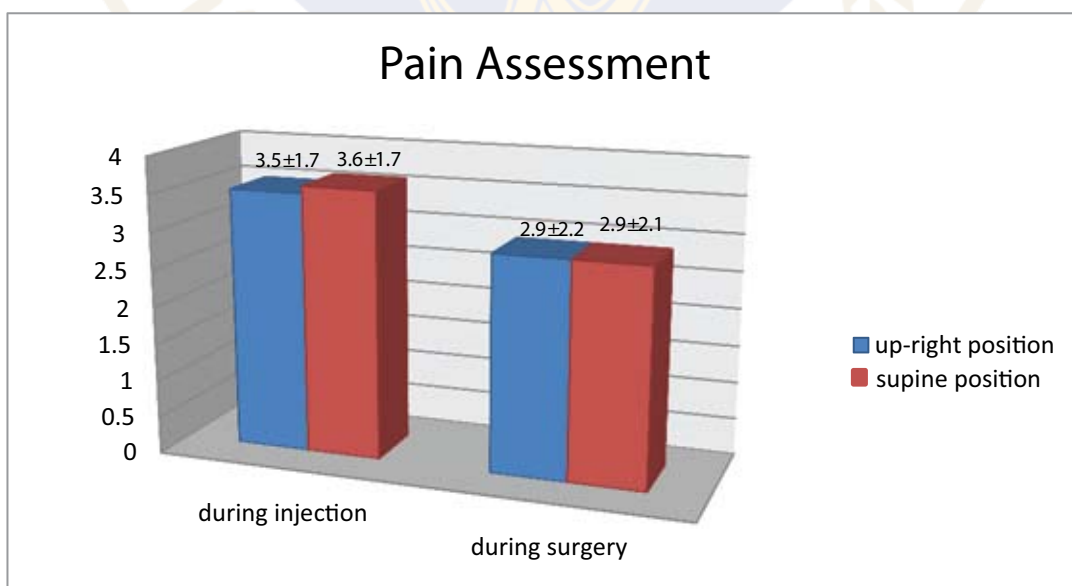


Figure 6 Pain assessment (via visual analog scale) during injection and surgery categorized according to the patient position

supine position with no statistically significant differences between the two ($P>0.05$). Pain assessment during surgery was 2.9 ± 2.2 for the up-right position and 2.9 ± 2.1 for the supine position; similarly, the differences were not statistically significant ($P>0.05$). Table 1 showed the amount of added local anesthetics in the up-right and supine positions was 37.93% and 44.83%, respectively.

Discussion

IANB is the most frequently used technique for local anesthesia for dental procedures in the mandible. In 1984 Kaufman¹ reported the failure rate of IANB was from 5-15% or 15-20%, and Palti et al² in 2011 reported higher percentages of failure in pulpal anesthesia. Previous studies have showed that failures of anesthesia may be caused by several factors, but alternatives to IANB are also available. The success rates of anesthesia for some of the alternative techniques were as follows: 25%–62% in conventional inferior alveolar technique, 16%–44% in Gow-Gates technique, and 13%–50% for the Vazirani-Akinosi technique. In a study, no significant difference ($p >.05$) in success rate was noted among these 3 techniques.³ Madan et al suggested that clinicians should investigate these techniques, rather than repeat the IANB after it has failed.³ Many studies¹³ have focused on enhancing the success rates of anesthesia but have not investigated the effects of patient position. Therefore, this research focused the effects of the patient position on the efficacy of IANB for lower third molar surgery.

In this study, the anesthesia attained by IANB was verified by using EPT to check

the pulpal anesthesia and the intraoral *pain assessment device* to test soft tissue numbness at gingival area. The results of this study showed that there was no statistic significant difference in the subjective onset of anesthesia between the up-right and supine positions. Although the objective onset in the supine position was faster than the up-right position, there was also no statistically significant difference between the two position. The duration of soft tissue anesthesia between these two positions was not significantly different, but the duration of anesthesia in the upright position (348.1 ± 112.5 mins) was slightly longer than in the supine position (337 ± 102.2 mins).

For a comfortable injection, the anesthesia should be warmed at room temperature, buffered ($pH=6.5$), and delivered with a novel device (Reed et al. 2012)⁸. The up-right and supine positions had no statistically significant difference in pain during injection. The pain during surgical removal of the lower third molar for the up-right position was less than the supine position but the difference in the pain between both the positions was not statically different. Even though no statistically significant differences were found in this study, a range of factors, as such as the previous experience and pain threshold of each patient, experience of the operator, anatomical variations at the injection site, etc., could have affected the efficacy of the anesthesia.

Although the subjective, objection onsets, and the duration of anesthesia was not different according to the patient position, we had to add or increase local anesthetics in both patient positions. The local anesthesia added in the up-

Table 1 Addition of local anesthetics according to the patient positions

	Up-right position		Supine position	
	Number	percentage	Number	percentage
No local anesthetic addition	11	37.93	13	44.83
Local anesthesia addition	18	62.07	16	55.17

right and supine patient positions were 62.07% and 55.17%, respectively, which indicated that the profoundness of anesthesia was less than ideal and a higher rate of failure of anesthesia (more than 50%) was noted.

We can conclude that the conventional IANB can be utilized in both upright and supine positions of the patient. Furthermore, the patient position can be adjusted according to the access without considering the failure or success of the anesthesia as the efficacy of IANB injection by direct technique is not dependent on patients' position.

Acknowledgment

This study could not have successfully completed without the kindness of the patients, who participated in the study. We would like to thank Dr. Bushara Ping, Dr. Muang Muang Latt, Dr. Minh Nguyen, Dr. Peiter Gozali, Dr. Pimrumpai Moranon, and the assistants, without whom this research could not have been completed. Additionally, the researchers are thankful to the Department of Oral and Maxillofacial Surgery, Faculty of Dentistry, Mahidol University for supporting this study.

Funding: Mahidol University Fund

Declaration of interests: None

Ethical Approval: The Committee in the Ethics of Research in Human Being of Dentistry and Pharmacy Mahidol University Institutional Review Board with Protocol No. MU DT/PY-IRB 2015/007.1702

References

1. Ashish Chakranarayan, Mukherjee B. Arched Needle Technique for Inferior Alveolar Mandibular Nerve Block. *J Maxillofac Oral Surg* 2013; 12: 113-6.
2. Dafna Geller Palti, Cristiane Machado de Almeida, Antonio de Castro Rodrigues, Jesus Carlos Andreo, José Eduardo Oliveira Lima. Anesthetic technique for inferior alveolar nerve block: a new approach. *J Appl Oral Sci* 2011; 19: 11-5.
3. Madan GA, Madan SG, Madan AD. Failure of inferior alveolar nerve block: exploring the alternatives. *J Am Dent Assoc* 2002; 133: 843-6.
4. Kiattavoracharoen S, Manosuthi P, Wongsirichat N, Boonsiriseth K. The anesthesia efficacy of intraosseous injection with QuickSleeper® and conventional injection in the lower third molar surgery. *M dent J* 2013; 33; 139-142.
5. Holliday R, Jackson I. Superior position of the mandibular foramen and the necessary alterations in the local anaesthetic technique: a case report. *Br Dent J* 2011; 210: 207-11.
6. Goldberg S, Reader A, Drum M, Nusstein J, Beck M. Comparison of the anesthetic efficacy of the conventional inferior alveolar, Gow-Gates, and Vazirani-Akinosi techniques. *J Endod* 2008; 34:1306-11. Available from doi: 10.1016/j.joen.2008.07.025. Epub 2008 Aug 30.
7. Zanette G, Manani G, Facco E, Mariuzzi ML, Tregnaghi A, Robb ND. Comparison between two regional anaesthesia techniques performed by inexperienced operators: the Gow-Gates block versus the Kenneth Reed block. *SAAD Dig* 2011; 27: 8-15.
8. Reed KL, Malamed SF, Fonner AM. Local Anesthesia part 2: Technical consideration. *Anesth Prog* 2012; 59: 127-137.
9. Yang I, Liu W, Gao Q. The anesthetic effect of Gow-Gates technique of inferior alveolar nerve block impacted mandibular third molar extraction. *West China J Stomatology* 2013; 31: 381.
10. Takasugi Y, Furuya H, Moriya K, Okamoto Y. Clinical evaluation of inferior alveolar nerve block by injection into the pterygomandibular space anterior to the mandibular foramen. *Anesth Prog* 2000; 47: 125-9.
11. Latt MM, Chewpreecha P, Wongsirichat N. Prediction of difficulty in impacted lower third molar extraction: Review literature. *M Dent J* 2015;35: 281-90.
12. Ping B, Kiattavorncharoen S, Saengsinavin C, Im P, Durward C, Wongsirichat N. The efficacy of an elevated concentration of lidocaine HCl in impacted lower third molar surgery. *J Dent Anesth Pain Med* 2015 Jun;15(2):69-76. Available from <http://dx.doi.org/10.17245/jdapm.2015.15.2.69>
13. Boonsiriseth K, Sirintawat N, Arunakul K, Wongsirichat N. Comparative study of the novel and conventional injection approach for inferior alveolar nerve block. *Int J oral Maxillofacial Surg* 2013; 42: 852-6.

