



Changes of the Transverse Dental Arch Dimension, Overjet and Overbite after Rapid Maxillary Expansion (RME)

Sasipa Thiradilok

Department of Advanced General Dentistry Faculty of Dentistry, Mahidol University.

Abstract

Objective: The aim of this study was to evaluate changes of the transverse dental arch dimension, overjet and overbite after the patients underwent the rapid maxillary expansion.

Materials and methods: The upper and lower dental models of the patients who showed maxillary constriction with posterior crossbite and underwent maxillary expansion were collected. The transverse dental arch dimensions at canine, first premolar, second premolar and first molar were measured before (T1) and after the expansion (T2). The overjet and overbite of both before and after expansion (T1,T2) were also recorded. Moreover, the dental models of patients with no posterior crossbite were collected as control. Paired *t*-test was performed to evaluate the changes of the dental arch dimensions after the expansion. The student *t*-test of the independent samples, treated and untreated groups, were selected for the statistical analysis.

Results: The maxillary interdental arch widths of canines, premolars and molars significantly increased after the expansion when compared to these before treatment. The amount of the expansion were 3.52 ± 2.25 mm, 4.55 ± 2.34 mm, 5.18 ± 1.80 mm, and 5.03 ± 2.04 mm for intercanine, inter-first premolar, inter-second premolar and intermolar widths, respectively. The changes on the lower arch were evaluated, although only the upper arch was expanded. The statistical significant increase in the mandibular interdental arch widths except the intercanine width, was found. The overjet and overbite decreased which showed the clinical changes after the maxillary expansion in the sagittal dental arch dimension. The upper and lower interdental arch widths of the maxillary constricted patients after maxillary expansion, were enlarged to be similar to the patients with no posterior crossbite.

Conclusion: The efficiency of the expansion therapy is to correct the constricted maxilla and enlarge both maxilla and mandibular transverse dental arch dimensions. After maxillary expansion, the posterior crossbite and the excessive overjet improved.

Keywords: rapid maxillary expansion (RME), maxillary constriction, posterior crossbite, dental arch dimensions, transverse changes, interdental arch widths

How to cite: Thiradilok S. Changes of the transverse dental arch dimension, overjet and overbite after rapid maxillary expansion (RME). *M Dent J* 2014; 34: 301-10.

Correspondence author:

Sasipa Thiradilok
Department of Advanced General Dentistry
Faculty of Dentistry, Mahidol University,
6 Yothi rd, Rajathevi, Bangkok 10400.

Tel: 02-200-7853

Fax: 02-200-7852

Received: 16 May 2014

Accepted: 1 September 2014

Introduction

The routine chief complaints of the patients who seek orthodontic treatment, mostly are spacing or crowding in the dental arches. For the patients with spacing, the treatment plan is to close the space which the patients easily agreed to because of no tooth extraction. On the other hand, the patients who have crowding in the dental arches, need additional space to relieve the problem. An orthodontist has to recognize the space required for each patient with crowded teeth. Tooth extraction is a certain choice for patients who have severe dental crowding. The other methods to gain more spaces in the dental arches are interproximal reduction of teeth or “stripping”, molar distalization, dental expansion, and orthopedic expansion of the maxilla or combination of all the alternatives.

The problem of transverse deficiencies in the upper arch can be clinically observed as posterior crossbite. The upper posterior teeth occlude inside of the lower teeth which indicates the maxillary narrowness. Many investigators¹⁻³ observed the posterior crossbite malocclusions in the different dentition periods. The prevalence of this malocclusion in the deciduous and mixed dentition was reported to be 8% and 12 %, respectively². The maxillary expansion therapy is suggested to solve this problem by enlarging the upper posterior teeth in the transverse direction. The orthodontists required both dental and skeletal effects for this expansion and many of them suggested to correct this form of malocclusion as early as possible^{2,3}.

Orthopedic maxillary expansion treatments have been used for more than 140 years and have been popularized since the mid-1960s. The expansion procedure was first introduced by Angell⁴ and White⁵ in 1860. Angell set a jackscrew on the upper dental arch across the roof of the mouth of a fourteen-year-old girl.

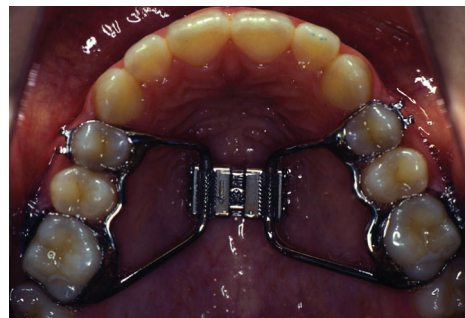


Figure 1 Rapid maxillary expansion (RME)

White placed a spiral spring through upper dental arch to force the teeth into the dental arch. Since this treatment has dentoskeletal effect, the treatment timing should begin in growing patients^{2,3,6,7}. The aim of the expansion treatment is to correct the skeletal discrepancy and to gain additional space in the dental arches to resolve crowding. Rapid maxillary expansion (RME) can be used effectively for this treatment approach (Fig 1).

Therefore, the objective of this study is to evaluate changes of maxilla and mandibular dental arch dimensions in transverse and sagittal dimensions in the patients at the beginning of treatment (T1) and after the expansion of the upper dental arch (T2) with rapid maxillary expansion (RME).

Materials and methods

Thirty pairs of dental models from the patients with posterior crossbite, were selected. The transverse distance at deciduous/permanent canines, deciduous first molars/permanent first premolars, deciduous second molars/permanent second premolars, mesiobuccal cusp tips of the first permanent molars, were measured directly on the upper and lower dental arches (Fig.2). The cusp tip was marked on the top point of the measured cusp using a 0.5 mm diameter pencil tip. All measurements made on the study casts were done by one investigator with an electronic digital caliper with sharpened tips (Fig.3),

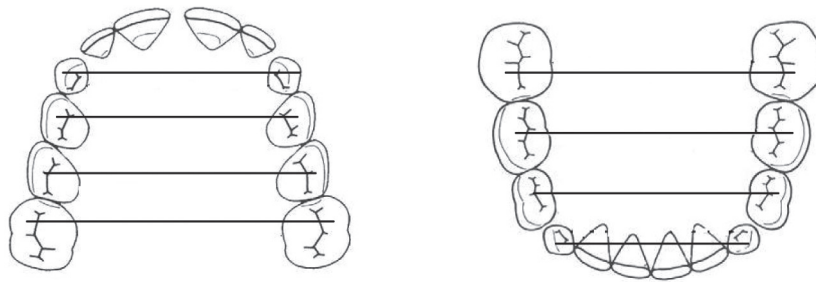


Figure 2 Model measurement at transverse direction

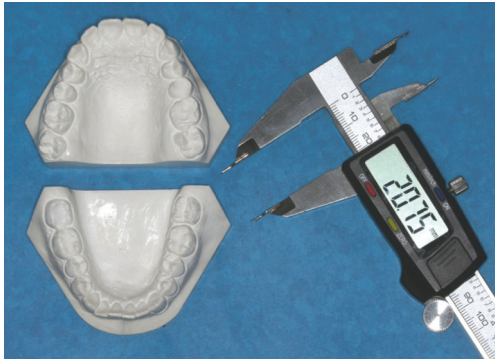

Figure 3 An electronic digital caliper with sharpened tips

recorded with the accuracy of 0.01 mm. The overjet and overbite which represented the sagittal and vertical distances, were also measured. In addition, the thirty pairs of dental models of the same group of patients after underwent expansion therapy with rapid maxillary expansion (RME), were collected. These models were treated to normal occlusion on the posterior teeth. All the transverse and sagittal directions were investigated at the same teeth positions. Each measurement were measured three times and the means of these values were recorded. Moreover, the thirty pairs of dental models with no posterior crossbite were collected as control samples. The transverse interdental arch width of the models with normal occlusion were measured at canine, premolars and molar, respectively. Overjet and overbite were also recorded.

To assess the reproducibility of the measurements, all measurements were repeated one month after the first measurement, on 15

randomly selected dental casts. The difference between the measurements did not exceed 0.05 mm, which was considered insignificant.

Statistical analysis

A descriptive analysis was performed for maxillary and mandibular arches measurements. The data obtained from the records before and after expansion treatment were compared using paired *t*-test (at $p \leq 0.05$). The comparison between the samples and control groups were tested using independent student *t*-test statistic (at $p \leq 0.05$). All analyses were performed using SPSS software version 18 for Windows (SPSS Inc.).

Results

The treatment effect of rapid maxillary expansion therapy in treated group on the maxillary and mandibular dental arches:

The transverse dental arch dimensions of the maxilla and mandible before and after expansion is described in Table 1. Means and standard deviations of the maxillary dental arch widths before underwent the maxillary expansion at canine, first premolar, second premolar and first molar, were 30.68 ± 1.77 mm, 37.54 ± 2.28 mm, 42.43 ± 2.42 mm, and 48.51 ± 2.57 mm. After the expansion, all of the transverse dental arch widths were 34.20 ± 2.70 mm, 42.10 ± 2.42 mm, 47.62 ± 2.63 mm, and 53.54 ± 2.70 mm, respectively. Furthermore, the intercanine, interpremolar and intermolar widths of the mandibular dental arch before expansion were 26.27 ± 1.56 mm, 32.35 ± 2.35

Table 1 Descriptive statistics before and after expansion of the maxillary and mandibular arches: the mean averages of the measurements, the standard deviation (S.D.) and the level of statistical significance (p value)

	Pre-treatment (T1)		After expansion (T2)	
	Mean	S.D.	Mean	S.D.
Maxillary dental arch (mm)				
Dental arch width (transverse)				
canine	30.68	1.77	34.20*	2.70
first premolar	37.54	2.28	42.10*	2.42
second premolar	42.43	2.42	47.62*	2.63
molar	48.51	2.57	53.54*	2.70
Mandibular dental arch (mm)				
Dental arch width (transverse)				
canine	26.27	1.56	26.72	2.21
first premolar	32.35	2.35	34.07*	2.44
second premolar	38.20	2.35	39.83*	2.70
molar	44.61	2.70	45.41*	2.71
Overjet (mm)	3.52	2.60	2.55	2.50
Overbite (mm)	2.73	2.10	2.50	1.63

* p < .05

mm, 38.20±2.35 mm, 44.61±2.70 mm. After treatment with RME on the upper arch, the transverse dental arch widths of the lower arch were 26.72±2.21 mm, 34.07±2.44 mm, 39.83±2.70 mm and 45.41±2.71 mm. The maxillary interdental arch widths of the canines, premolars and molars significantly increased after the expansion when compared to these distances before treatment. The effect of the enlargement on the upper arch showed that the mandibular interdental arch widths also statistically increased except the intercanine arch width. Figure 4 and 5 showed the mean of the maxillary and mandibular dental arch widths before and after treatment.

All measurements after underwent maxillary expansion showed the enlargement of the maxillary and mandibular transverse dental arch widths when compared to the values before the expansion. The changes were 3.52±2.25 mm, 4.55±2.34 mm, 5.18±1.80 mm, and

5.03±2.04 mm for intercanine, inter-first premolar, inter-second premolar and intermolar widths, respectively. Although, the expansion was performed on the upper dental arch, the enlargement of the lower interdental arch was detected. It showed the amount of 0.44±1.70 mm of the intercanine width, 1.73±1.80 mm of the inter-first premolar, 1.63±2.26 mm of the inter-second premolar and 0.80±1.90 mm of the first molar (Table 2). In addition, overjet and overbite were measured before and after the expansion. These values decreased which showed the clinical changes of the sagittal dental arch dimension after the expansion of transverse dimension. However, there was no statistic difference of the sagittal dimension after the treatment.

The comparison of patient group and control sample group

Means of the transverse dental arch

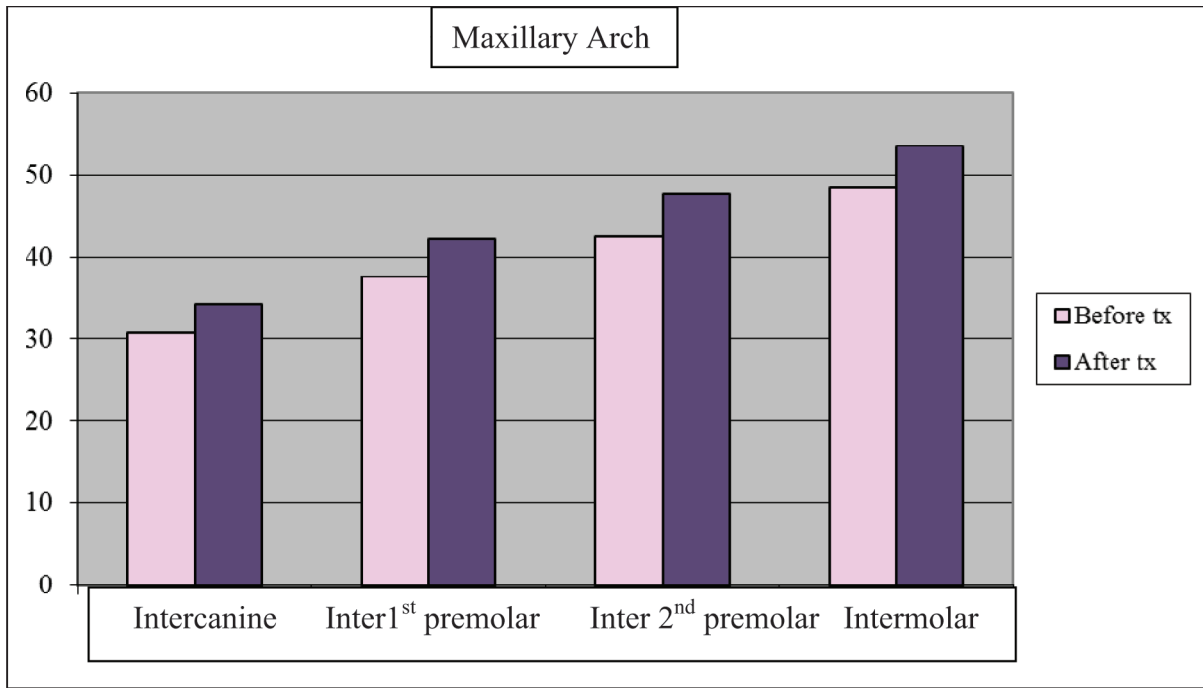


Figure 4 Means of the maxillary dental arch width measurement before and after maxillary expansion

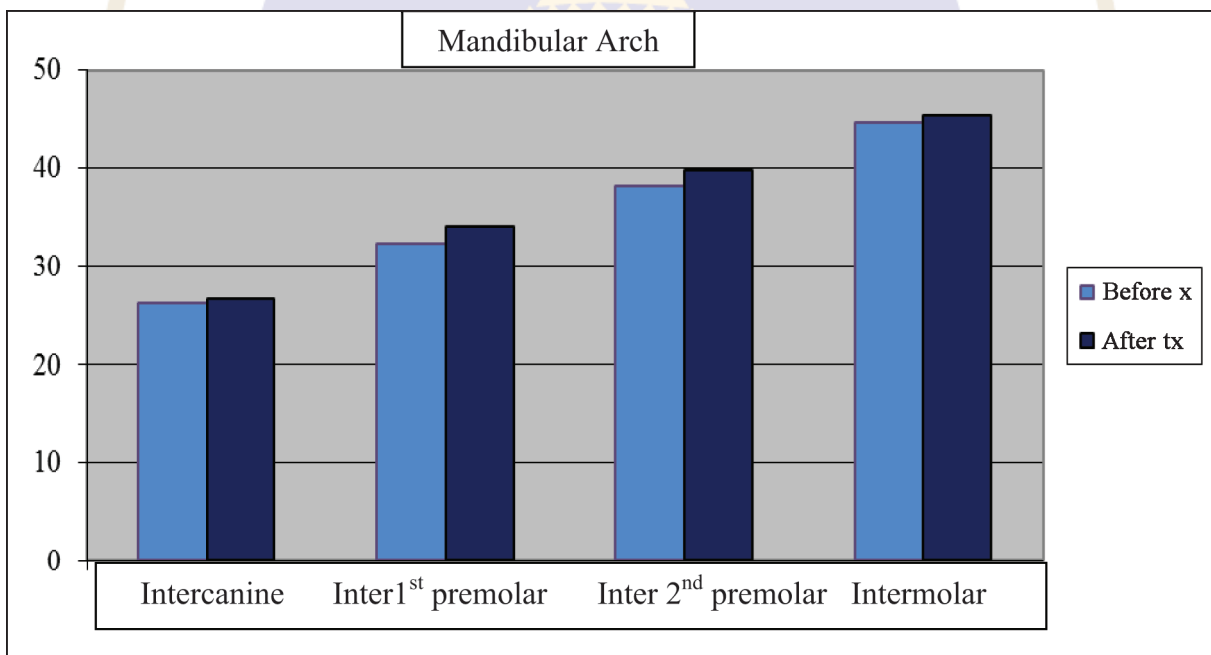


Figure 5 Means of the mandibular dental arch width measurement before and after maxillary expansion

widths between patients with narrow maxillary transversal dental arch before expansion and untreated sample group is shown in Table 3. In upper arch, the untreated control group showed the wider distance of all interdental arch widths at canine, first premolar, second premolar and first molar. They were 34.31 ± 1.99

mm, 41.51 ± 2.70 mm, 46.59 ± 2.71 mm and 52.93 ± 2.20 mm, respectively. In the lower arch, the interdental arch width of the control group were 26.90 ± 1.60 mm, 34.8 ± 2.22 mm, 40.83 ± 2.70 mm and 46.22 ± 2.67 mm. There were statistically significant differences of the dental arch widths except lower intercanine width

Table 2 Descriptive statistics showed the width differences before and after the expansion (T2-T1): the mean averages of the differences and the standard deviation (S.D.)

	Differences (T2-T1)	
	Mean	S.D.
Maxillary dental arch (mm)		
Dental arch width (transverse)		
canine	3.52	2.25
first premolar	4.55	2.34
second premolar	5.18	1.80
molar	5.03	2.04
Mandibular dental arch (mm)		
Dental arch width (transverse)		
canine	0.44	1.70
first premolar	1.73	1.80
second premolar	1.63	2.26
molar	0.80	1.90
Overjet (mm)	-0.97	1.55
Overbite (mm)	-0.23	0.49

Table 3 Descriptive statistics showed the width before expansion and the control group: the mean averages of the measurements, the standard deviation (S.D.) and the level of statistical significance (p value)

	Pre-treatment (T1)		Control group	
	Mean	SD	Mean	SD
Maxillary dental arch (mm)				
Dental arch width (transverse)				
canine	30.68	1.77	34.31*	1.99
first premolar	37.54	2.28	41.51*	2.70
second premolar	42.43	2.42	46.59*	2.71
molar	48.51	2.57	52.93*	2.20
Mandibular dental arch (mm)				
Dental arch width (transverse)				
canine	26.27	1.56	26.90	1.60
first premolar	32.35	2.35	34.80*	2.22
second premolar	38.20	2.35	40.83*	2.70
molar	44.61	2.70	46.22*	2.67
Overjet (mm)	3.52	2.60	2.72	1.09
Overbite (mm)	2.73	2.10	2.67	1.14

* p < .05

between treated and control groups. Although, the excess overjet of the untreated patients before the expansion was detected, there was no significant difference when compared to control group. Means of the transverse upper dental arch widths of the treated and of the control groups were displayed in Figure 6.

Means and standard deviations of the interdental arch widths between the patient group after maxillary expansion and untreated sample group are described in Table 4. There were no significant differences between the maxillary and mandibular interdental arch widths of the control group and the treated group. In Figure 7, the comparison of mandibular interdental arch widths between control and patient groups is shown.

Discussion

The maxillary expansion therapy is indicated to the patients who have maxillary transverse deficiency. The symptom is clinically noticed by posterior crossbite. Aim of the expansion therapy with maxillary expansion

appliances is to enlarge the transverse upper dental arch to reach the normal occlusion by correcting the posterior crossbite. This present study evaluated the transverse changes of the intercanine, interpremolar and intermolar widths in the upper and lower dental arches after the expansion therapy. The dental casts of untreated sample group with no posterior crossbite, were collected to serve as control.

Maxillary expander is used to treat the transverse deficiency on the maxillary dental arch. It is clear that the enlargement of the upper arch should be detected whether it is the skeletal or dental effect. Although, the anchorage teeth mostly are first premolars and first molars, the expansion was also found at transverse dimensions of all posterior teeth e.g. canines and second premolars. The enlargement of transverse maxillary dental arch dimensions in this present study after the expansion therapy showed the effectiveness of the appliances, remarkably. There were 3.52 ± 2.25 mm, 4.55 ± 2.34 mm, 5.18 ± 1.80 mm, and 5.03 ± 2.04 mm of maxillary intercanine,

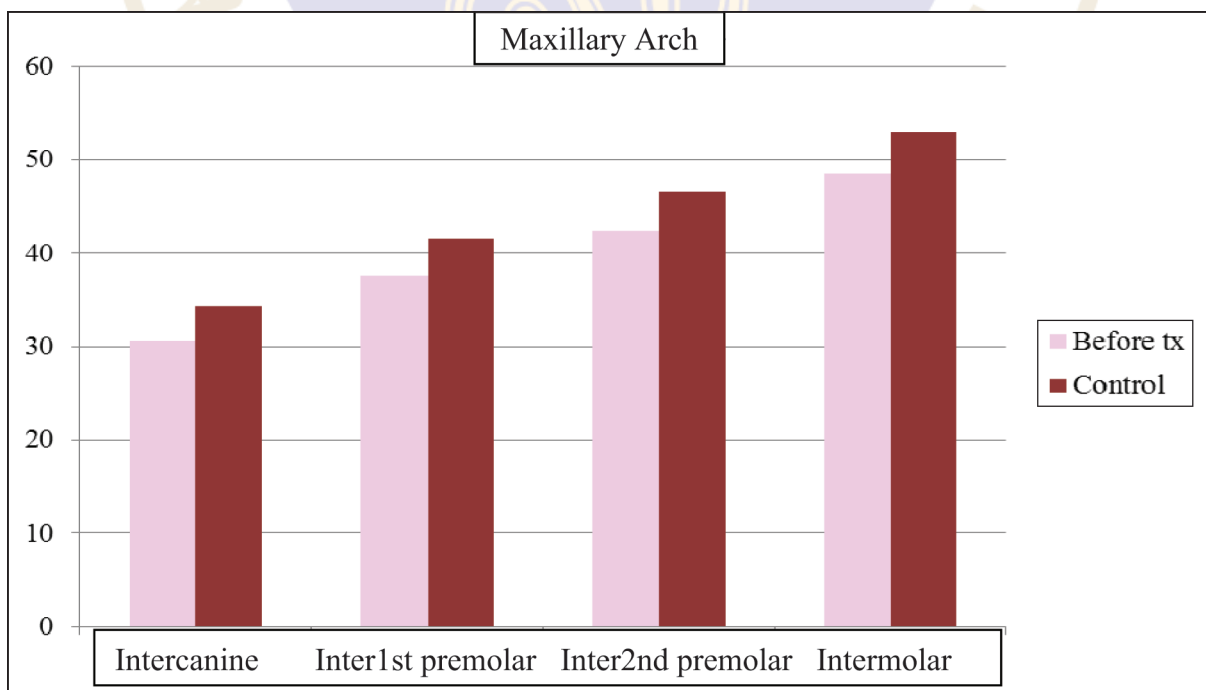


Figure 6 Means of the maxillary dental arch width measurement before maxillary expansion compared to control group

inter-first premolar, inter-second premolar and intermolar dental arch widths, respectively. The results showed a significant increase in all measurements when compared before and after the expansion. These increased measurements are similar to the findings of

Table 4 Descriptive statistics showed the width after expansion and the control group: the mean averages of the measurements, the standard deviation (S.D.) and the level of statistical significance (p value)

	After expansion (T2)		Control group	
	Mean	SD	Mean	SD
Maxillary dental arch				
Dental arch width (transverse)				
canine	34.20	2.70	34.31	1.99
first premolar	42.10	2.42	41.51	2.70
second premolar	47.62	2.63	46.59	2.71
molar	53.54	2.70	52.93	2.20
Mandibular dental arch				
Dental arch width (transverse)				
canine	26.72	2.21	26.9	1.60
first premolar	34.07	2.44	34.8	2.22
second premolar	39.83	2.70	40.83	2.70
molar	45.41	2.71	46.22	2.67
Overjet	2.55	2.50	2.72	1.09
Overbite	2.50	1.63	2.67	1.14

* p < .05

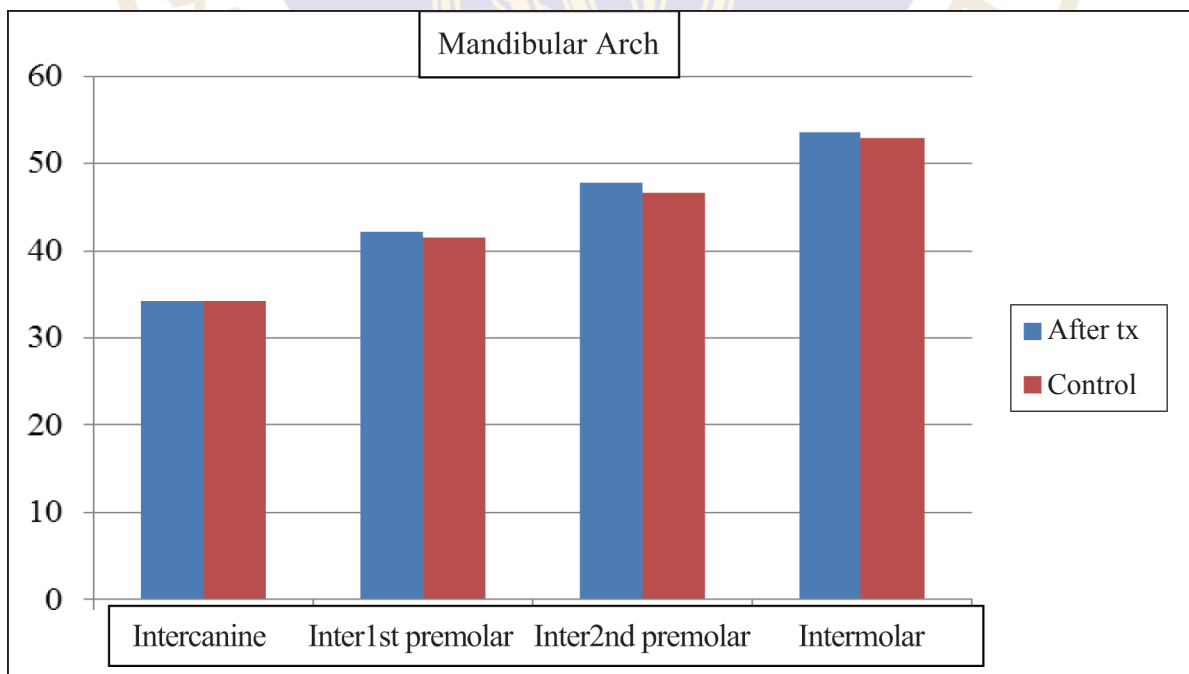


Figure 7 Means of the mandibular dental arch width measurement after maxillary expansion compared to control group

some authors^{7,8,11-13}. The study of Geran et al⁷ determined the changes of dental arch dimensions of the patients who were treated with acrylic splint rapid maxillary expander. They found that the changes were 4.0 ± 1.6 mm, 5.3 ± 2.0 mm, 5.3 ± 2.0 mm, and 4.3 ± 2.0 mm for intercanine, inter-first premolar, inter-second premolar and intermolar widths. Moreover, Gurel et al⁸ collected the dental casts of the patients who underwent RME with a splint-type tooth and tissue-borne appliances. They reported the changes of 6.6 ± 3.09 mm for intercanine width, 7.7 ± 2.9 mm for inter-first premolar width and 7.7 ± 2.8 mm for intermolar width after expansion.

In addition, the expansion on the lower arch was evaluated in this present study, although there was no active expansion for the mandible during the investigation periods. The concurrence increase in the transverse lower arch dimensions was found significantly after the expansion on the upper arch except for the lower intercanine width. The lower dental arch dimensions after the upper arch expansion of this present study were 26.72 ± 2.21 mm, 34.07 ± 2.44 mm, 39.83 ± 2.70 mm and 45.41 ± 2.70 mm for intercanine, interfirst- and inter-second premolar and intermolar widths, respectively. The amount of the enlargement is similar to the study of Lima et al⁹. They reported the intercanine widths of 26.36 ± 1.90 mm and the intermolar width of 45.13 ± 1.98 mm after the maxillary expansion. CÖrekc and GÖyenc¹³ investigated the changes of intercanine and intermolar widths on the upper and lower dental arches after the expansion of the fan type and rapid maxillary expansion appliances. They found the significant increase in the maxillary arch widths but there was no significant increase in the mandibular arch. It may be assumed from this study that the increase in the lower transverse arch

dimensions associated with the expansion of the maxilla, was the result of the buccal uprighting of the mandibular posterior teeth. The lower teeth moved from lingual to buccal position to occlude the expanded upper posterior teeth. This occurrence may due to the functional occlusion of the patient.

Moreover, the control group with no posterior crossbite were collected. The comparison of the interdental arch widths between the group of constricted maxilla and control group showed the significant differences of these values ($p < 0.05$). The patients with constricted maxilla had the smaller maxillary and mandibular interdental arch widths when compared to the patients with normal occlusion. The significant differences of the lower interdental arch widths of the patients with posterior crossbite when compared to the control group, were also found except the lower intercanine width. These results are similar to the study of Moriyasu et al¹⁸ who compared the maxilla and mandibular widths of the patients and found that these widths were significantly smaller than the control group ($p < 0.01$) at the start of treatment. The study of Geran et al⁷ reported the significant narrower of the maxillary and mandibular dental arch widths of the treated group at the time before treatment than the corresponding dental arches of the subjects in the control group. After the patients underwent the maxillary expansion in this study, all measurements of the maxillary and mandibular dental arch widths between the patient and control groups were compared. It was found that there was no significant difference between these two groups. It can be assumed that the expansion on the maxilla enlarged the dental arches both in upper and lower to reach the dental arch widths of the normal patient with no maxillary deficiency.

In conclusion, the expansion of the constricted maxillary dental arch is effective to correct the transverse deficiency. The enlargement of the mandibular dental arch widths correspond to the maxillary arch was found, although there was no active expansion of the mandibular dental arch. The posterior crossbite after the expansion improved to achieve the normal occlusion when compared with the control group. The long term evaluation after expansion treatment to retention period should be focused in the further studies.

Funding: None

Competing interests: None declared

Ethical approval: The Mahidol University Institutional Review Board with Protocol COE. No. MU-DT IRB 2014/DT017

References

1. Erdinc AE, Ugur T, Erbay EA. Comparison of different treatment techniques for posterior crossbite in the mixed dentition. *Am J Orthod Dentofacial Orthop* 1999; 116: 287-300.
2. Kutin G, Hawes RR. Posterior crossbites in the deciduous and mixed dentitions. *Am J Orthod Dentofacial Orthop* 1969; 56: 491-504.
3. Sari Z, Uysal T, Usumez S, Basciftci AF. Rapid Maxillary Expansion. Is it Better in the Mixed or in the Permanent Dentition? *Angle Orthod* 2003; 73: 654-661.
4. Angell EH. Treatment of irregularity of the permanent or adult teeth. *Dental Cosmos* 1860; 1: 540-544.
5. White JD. Expanding the jaw. *Dent Cosmos* 1860; 1: 280-282.
6. McNamara JA. Maxillary transverse deficiency. *Am J Orthod Dentofacial Orthop* 2000; 117: 567-70.
7. Geran RG, McNamara JA Jr, Baccetti T, Franchi L, Shapiro LM. A prospective long-term study on the effects of rapid maxillary expansion in the early mixed dentition. *Am J Orthod Dentofacial Orthop* 2006; 129: 631-40.
8. Gurel HG, Memili B, Erkan M, Sukurica Y. Long term Effects of Rapid Maxillary Expansion followed by Fixed Appliances. *Angle Orthod*. 2010; 80: 5-9.
9. Lima AC, Lima AL, Filho RM, Oyen OJ. Spontaneous mandibular arch response after rapid palatal expansion: A long-term study on Class I malocclusion. *Am J Orthod Dentofacial Orthop* 2004; 126: 576-82.
10. Belluzzo RHL, Faltin Junior K, Lascala CE, Vianna LBR. Maxillary constriction: Are there differences between anterior and posterior regions? *Dental Press J Orthod* 2012; 17: 1-6.
11. Doruk C, Bicakci AA, Basciftci FA, Aqar U, Babacan H. A Comparison of the Effects of Rapid Maxillary Expansion and Fan-Type Rapid Maxillary Expansion on Dentofacial Structures. *Angle Orthod* 2004; 74: 184-194.
12. Weissheimer A, de Menezes LM, Mezomo M, Dias DM, de Lima EM, Rizzato SM. Immediate effects of rapid maxillary expansion with Haas-type and Hyrax-type expanders: A randomized clinical trial. *Am J Orthod Dentofacial Orthop* 2011; 140: 366-76.
13. CÖrekc B, GÖyenc YB. Dentofacial changes from fan-type rapid maxillary expansion vs traditional rapid maxillary expansion in early mixed dentition A prospective clinical trial. *Angle Orthod* 2013; 83: 842-850.
14. Lionea R, Franchi L, Cozza P. Does rapid maxillary expansion induce adverse effects in growing subjects? A systematic review. *Angle Orthod* 2013; 83: 172-182.
15. Lagrave`re MO. Transverse, vertical, and anteroposterior changes from bone-anchored maxillary expansion vs traditional rapid maxillary expansion: A randomized clinical trial. *Am J Orthod Dentofacial Orthop* 2010; 137: 304-312.
16. Agarwal A, Mathur R. Maxillary Expansion. Review article. *Int J Clin Pediatr Dent* 2010; 3: 139-146.
17. Baccetti T et al. Treatment Timing for Rapid Maxillary Expansion. *Angle Orthod* 2001; 71: 343-350.
18. Moriyasu K et al. Longitudinal clinical study on the effect of slow maxillary expansion with removable appliances. *Pediatr Dent J* 2010; 20: 78-83.