

Palatal remaining coronal cervical tooth structure increases the survival rate from unrestorable fractures in endodontically treated maxillary anterior teeth restored with resin composite restorations: A retrospective cohort study

Pimnara Phengudom¹, Danuchit Banomyong¹, Titalee Jirathyanatt¹,
Yaowaluk Ngoenwivatkul², Warattama Suksaphar³

¹ Department of Operative Dentistry and Endodontics, Faculty of Dentistry, Mahidol University, Bangkok, Thailand

² Department of Community Dentistry, Faculty of Dentistry, Mahidol University, Bangkok, Thailand

³ Department of Endodontics, Faculty of Dentistry, Rangsit University, Pathum Thani, Thailand

Objectives: This aim of this retrospective cohort study was to investigate the effect of the remaining coronal cervical tooth structure (CCTS) on survival rates compared with unrestorable fracture of endodontically treated maxillary anterior teeth (ETT) restored with direct resin composite (DRC).

Methods and materials: Based on the inclusion and exclusion criteria, the dental records and radiographs of ETT restored with DRC were collected from the dental charts of patients who received endodontic treatment and attended recall(s) during 2007–2019. The different remaining CCTSs were defined as: (1) complete CCTS, (2) partial CCTS with a palatal side, (3) partial CCTS without a palatal side, and (4) no CCTS. The frequency of unrestorable fractures was determined. The survival rates compared with unrestorable ETT fracture with different remaining CCTSs were calculated and statistically analyzed using the Cox proportional-hazard model.

Results: The study comprised 126 maxillary anterior ETT restored with DRC. The average recall period was 36 months, the survival rate of ETT with complete CCTS and partial CCTS with a palatal side was 94.5% and 95.8%, respectively. The survival rates of the partial CCTS without a palatal side (78.6%) and no CCTS (44.4%) were significantly lower compared with the ETT ($p < .05$).

Conclusion: The frequency of unrestorable fracture in maxillary anterior ETT restored with DRC in complete or partial CCTS with a palatal side was significantly lower compared with partial CCTS without a palatal side.

Keywords: Cervical tooth structure, endodontically treated teeth, resin composite, survival rate, unrestorable fracture

How to cite: Phengudom P, Banomyong D, Jirathyanatt T, Ngoenwivatkul Y, Suksaphar W. Palatal remaining coronal cervical tooth structure increases the survival rate from unrestorable fractures in endodontically treated maxillary anterior teeth restored with resin composite restorations: A retrospective cohort study. M Dent J 2021; 41: 132-138.

Introduction

An unrestorable fracture is a common failure in endodontically treated teeth (ETT) [1]. ETT are susceptible to fracture due to extensive loss of tooth structure from dental caries, coronal fracture, or pre-existing large restorations [2]. Selecting the appropriate restoration for an ETT is based on the remaining tooth structure and functional force that

will be applied to it [3]. A systematic review found that anterior ETT with a minimal to moderate loss of tooth structure may be conservatively restored with direct resin composite (DRC) to achieve an acceptable fracture resistance [4]. However, a full coverage restoration may be necessary if a significant loss (>50%) of tooth structure is present [4]. Furthermore, the location of the remaining tooth structure is important for ETT fracture resistance [5]. *In vitro* studies [5, 6] in maxillary anterior ETT

Correspondence author: Danuchit Banomyong

Department of Operative Dentistry and Endodontics, Faculty of Dentistry, Mahidol University

6 Yothi Road, Ratchathewi, Bangkok 10400, Thailand

Tel. +66 2200 7825-6 E-mail: danuchit.ban@mahidol.ac.th

Received: 28 December 2020

Revised: 19 March 2021

Accepted: 21 March 2021

restored with a post and crown demonstrated that a complete ferrule may not be the most important feature contributing to fracture resistance. A more important feature may be the presence of coronal cervical tooth structure (CCTS) in a location that can resist occlusal loading, which is the palatal side in maxillary anterior teeth.

The classic retrospective study by Sorensen and Martinoff in 1984 [7] is the only study that reported the survival of maxillary anterior ETT separately from mandibular anterior ETT. In their study, the maxillary anterior ETT restored with DRC survived as long as those restored with full-coverage crowns. However, the survival assessment in their study was not limited to unrestorable fractures, and included other failures as well. However, no clinical study has evaluated and identified the factors that protect against an unrestorable fracture in anterior ETT restored with DRC. Previous *in vitro* studies [5, 6] demonstrated that the location of the remaining CCTS may affect the fracture resistance in maxillary anterior ETT restored with a crown. Moreover, there is no clinical evidence concerning the effect of the remaining CCTS on the survival from unrestorable fracture in maxillary anterior ETT restored with DRC.

Therefore, the aim of this retrospective cohort study was to investigate the effect of the remaining CCTS on the survival rate from unrestorable fractures in maxillary anterior ETT restored with DRC.

Materials and Methods

The study protocol was approved by the Institutional Ethics Review Committee (MU-DT/PY-IRB 2018/014.2302). The data was collected from the dental records of patients who attended recalls from January 2007 to May 2019. Maxillary anterior ETT with DRC restorations were included in the study based on the inclusion and exclusion criteria.

Inclusion and exclusion criteria

The inclusion criteria were: (1) maxillary anterior ETT with a mature root, (2) ETT restored with a DRC restoration, (3) ETT with at least one occluding tooth (natural tooth or fixed dental prosthesis), and (4) ETT with at least a one-year recall period.

The exclusion criteria were: (1) ETT diagnosed as a cracked tooth, (2) ETT restored with a temporary restoration or direct/indirect veneer, (3) ETT with alveolar bone loss more than half of root length due to periodontal disease, (4) ETT with a history of procedural error(s) during endodontic treatment that compromised the strength of the tooth structure, and (5) ETT undergoing orthodontic treatment.

Endodontic and restorative treatments

In brief, endodontic treatment was performed using rubber dam isolation. Caries removal (if any), access opening, and working length determination were performed. The root canals were prepared by the crown-down technique using hand and/or rotary Ni-Ti files with copious irrigation with 2.5% sodium hypochlorite and 17% EDTA (M-Dent, Bangkok, Thailand). The root canals were medicated with calcium hydroxide paste for at least 1–4 weeks. The prepared root canals were obturated with gutta percha and root canal sealer [zinc oxide eugenol or epoxy resin sealer (AH Plus, Dentsply-Maillefer, Tulsa, OK, USA)], using lateral or warm vertical compaction to 1–2 mm below the cemento-enamel junction.

Most DRC restorations were placed as a permanent restoration, except when an intermediate DRC restoration was required before full-coverage crown placement. When placing an intermediate restoration, the access cavities were lined with an ~1–2 mm thick temporary filling (Cavition, GC corp., Tokyo, Japan). A 1–2 mm thick glass-ionomer cement lining (Fuji VII, GC corp., Tokyo, Japan) was placed over the gutta percha/sealer filling or temporary filling. The cavities were bonded with an etch-and-rinse adhesive (Adper Single Bond 2, 3M ESPE, St. Paul, MN, USA) per the manufacturer's

instructions. Nano-hybrid resin composite (Z350XT, 3M ESPE) was incrementally filled into the cavities using 2-mm thick layers and light-cured using a LED light-curing unit (Bluephase, Ivoclar Vivadent, Schaan, Liechtenstein) for 20 s each. The patients were periodically recalled after complete endodontic and restorative treatment.

Data collection

An overview of the methodology of this retrospective cohort study is presented in Figure 1. The following data were collected from dental records and radiographs: age, sex, and recall periods of each patient. The following ETT factors were identified: (1) tooth type (incisor/canine), (2) remaining CCTS sides, (3) incidence of tooth fracture (yes/no), and (4) fracture type (tooth structure, restoration, or combination) and the site, coronal, coronal-root, or root).

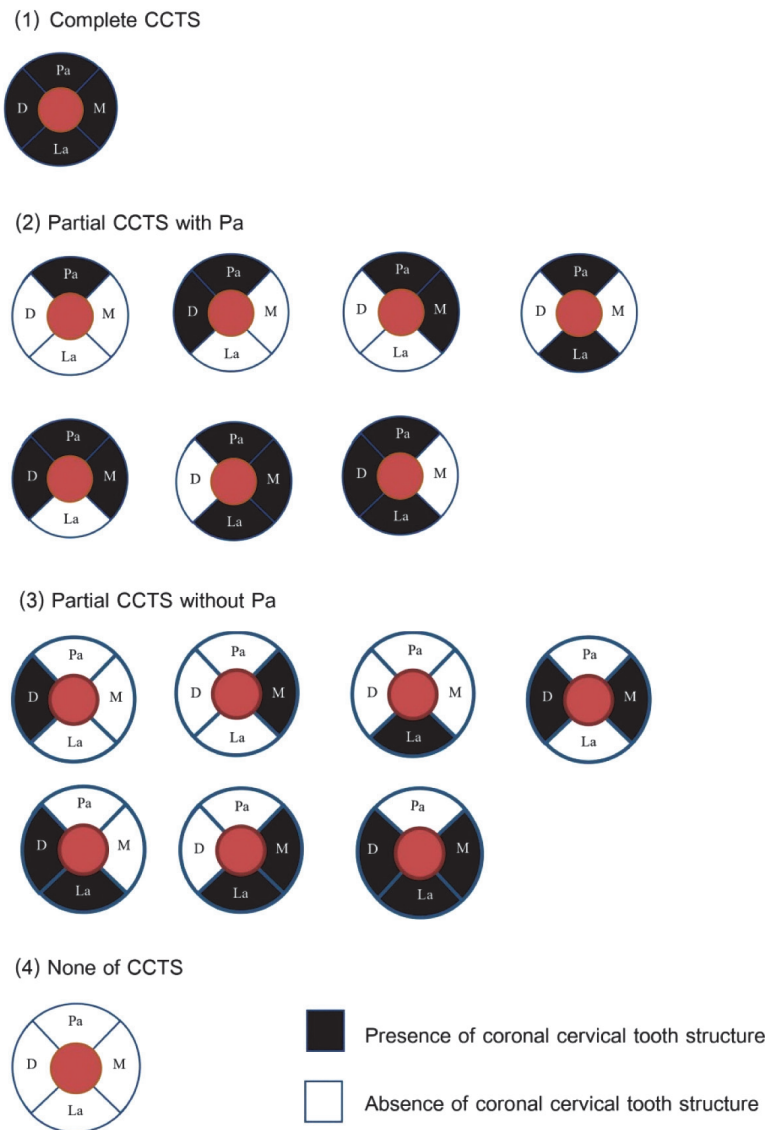


Figure 1 Illustrations of a cross-sectional view of the four groups of maxillary anterior endodontically treated teeth with different remaining coronal cervical tooth structure (CCTS): (1) *complete CCTS*, four sides completely present; (2) *partial CCTS with a palatal side*, other side(s) were lost, but the palatal side was present; (3) *partial CCTS without a palatal side*, the palatal side was lost, but at least one of the other side(s) was present; and (4) *no CCTS*, all sides were lost.

The remaining CCTS was identified based on the remaining walls at the cervical one-third area, i.e. mesial, distal, palatal, and labial side. The ETT with different remaining CCTSs were categorized into four groups (Figure 1): (1) *complete CCTS*, four sides present; (2) *partial CCTS with a palatal side*, other side(s) were lost but the palatal side was present; (3) *partial CCTS without a palatal side*, the palatal side was lost, but at least one of the other sides was present.; and (4) *no CCTS*, all sides were lost.

Unrestorable fracture identification

Any fracture was identified from the dental records. The fracture type was defined as within the tooth structure, restoration, or combination, and the fracture site was classified as coronal,

coronal-root, or root. The fractures were classified into restorable or unrestorable. The definition of a restorable fracture was a fracture that could be repaired or replaced with a new restoration. The definition of an unrestorable fracture was a fracture with extensive destruction of tooth structure leading to tooth extraction (e.g. a sub-gingival fracture for which crown lengthening or orthodontic extrusion was not appropriate, inadequate ferrule, unfavorable crown-root ratio after fracture, or a vertical root fracture).

The outcomes of survival from unrestorable fracture in maxillary anterior ETT were categorized as (1) *survived* (with no fracture or the fracture was restorable), and (2) *not survived* (with an unrestorable fracture) (Figure 2).

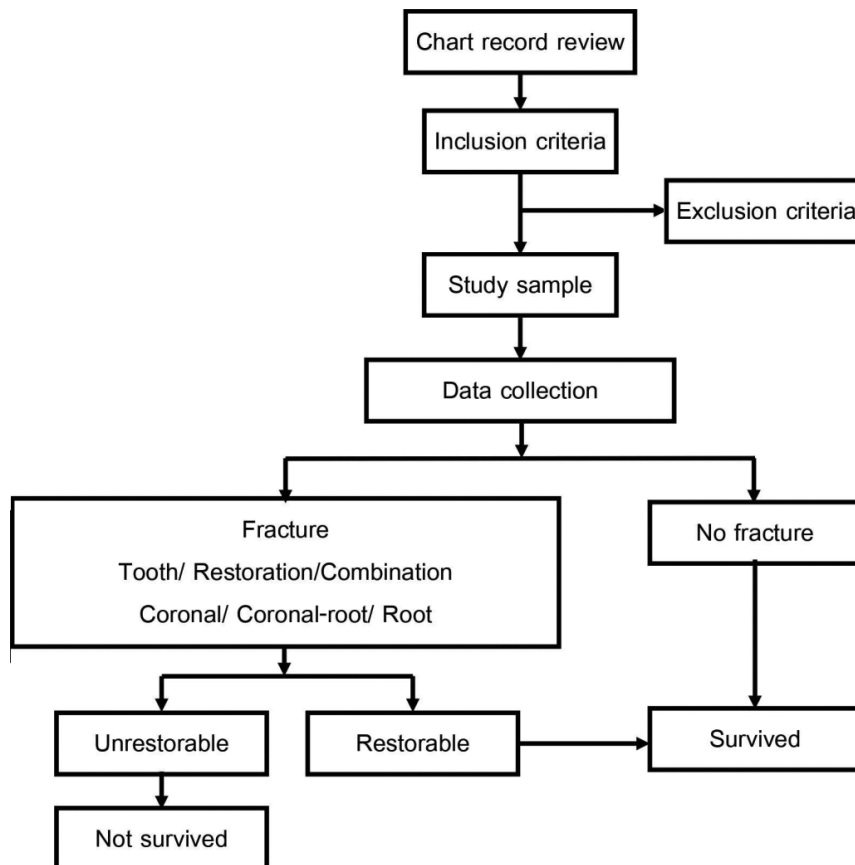


Figure 2 An overview of the methodology in this retrospective cohort study.

Statistical Analysis

Statistical analysis was performed using SPSS version 22 for MAC (SPSS Inc., Chicago, IL, USA) with a significance level set at $p < .05$. The Cox proportional-hazard model was used to evaluate the effect of the remaining CCTS on the survival rates from unrestorable fracture in the maxillary anterior ETT and the outcome of the complete CCTS group was set as a reference value for comparison.

Results

This study comprised 126 maxillary anterior ETT with DRC in 81 females (64.3%) and 45 males (35.7%) aged 11–78 (51 ± 14.4) years old. We evaluated 86 incisors (68.3%), and 40 canines (31.7%). The recall periods ranged from 12–113 months, with a mean of 36 ± 21.5 months. Based

on the remaining CCTS, the number of teeth in the groups was 55 teeth with complete CCTS, 48 teeth with partial CCTS with a palatal side, 14 teeth with a partial CCTS without a palatal side, and 9 teeth without CCTS. The details of the subgroups, the remaining sides, and the partial CCTS with and without a palatal side are presented in Table 1.

The overall survival rate of the 126 maxillary anterior ETT was 89.7% with 13 teeth (10.3%) extracted because of unrestorable fractures. One tooth had a coronal-root fracture within its structure. The remaining 12 teeth demonstrated tooth structure and restoration fractures, of which 9 teeth had a coronal fracture and 3 teeth had a coronal-root fracture. The survival rate of the ETT with complete CCTS, partial CCTS with a palatal side, partial CCTS without a palatal side, and no CCTS was 94.5%, 95.8%, 78.6%, and 44.4%, respectively (Table 2).

Table 1 Remaining sides and numbers of teeth in all subgroups of partial coronal cervical tooth structure (CCTS) with and without a palatal side.

Partial CCTS with Pa		Partial CCTS without Pa	
Remaining CCTS side	Number (teeth)	Remaining CCTS side	Number (teeth)
Pa	2	M	4
MPa	1	D	4
DPa	3	La	1
LaPa	14	MD	2
MDPa	8	DLa	2
MLaPa	12	MDLa	1
DLaPa	8		
Total	48	Total	14

Pa- palatal, M- mesial, D- distal, and La-labial

Table 2 Survival from unrestorable fracture of maxillary anterior ETT with different remaining coronal cervical tooth structure.

Coronal cervical tooth structure (CCTS)	Number of teeth	Survival [n (%)]	Hazard ratio (95%CI)	p value
Complete CCTS	55	52 (94.5)	1	Reference
Partial CCTS with Pa	48	46 (95.8)	0.69 (0.12, 4.17)	0.69
Partial CCTS without Pa	14	11 (78.6)	6.21 (1.23, 31.48)	0.03*
No CCTS	9	4 (44.4)	16.78 (3.74, 75.21)	<0.01*

Pa- palatal side; *significant difference using Cox-regression analysis ($p < .05$).

Compared with the complete CCTS teeth, the survival rate of the partial CCTS with a palatal side teeth was not significantly different ($p \geq .05$) (Table 2). In contrast, the survival rates of the no CCTS and partial CCTS without a palatal side teeth were significantly lower compared the complete CCTS teeth ($p < .05$). The hazard ratio of the ETT with no CCTS and partial CCTS without a palatal side were 16.78-fold (HR: 16.78; 95%; CI: 3.74, 75.21; $p < .01$) and 6.21-fold (HR: 6.21; 95%; CI: 1.23, 31.48; $p = .03$), respectively, more likely to have an unrestorable fracture than those with a complete CCTS.

Discussion

In this study, the survival rate of ETT with palatal CCTS was 94.5–95.8% and without a palatal side was 44–78.6% when restored with resin composite. Clinically, partial loss of CCTS in ETT is common; and ETT with an ideal complete CCTS is rare. For maxillary anterior ETT with incomplete coronal structure, the location of the intact structure affects its fracture resistance [5]. In our study, the presence of palatal CCTS might act as a ferrule to withstand and distribute lateral functional forces, and reduce the likelihood of an unrestorable fracture in ETT [9].

The present study demonstrated that the survival rate of ETT with partial CCTS with a palatal side was higher than those without a palatal side, and comparable to those with complete CCTS. These results are in agreement with the results of *in vitro* studies in maxillary anterior ETT restored with fiber posts and crowns [5, 6] that reported a higher fracture resistance when a palatal ferrule was present. A complete CCTS may not be the most important factor affecting fracture resistance. The location of the CCTS had the most effect on the fracture resistance for ETT restored with posts and crowns and those restored with resin composite.

Maxillary anterior teeth generally resist lateral occlusal forces. Torbjørner, *et al.* [10] demonstrated that lateral occlusal forces repeatedly developed compression stress at the loading side and tension stress at the opposite side, which eventually induced fatigue fracture. The palatal side of the maxillary anterior teeth is placed under tensile stress from a lateral force. Therefore, intact palatal tooth structure at the cervical area provides the support to withstand the force and reduces the likelihood of fracture.

In the present study, the maxillary anterior ETT with a loss of palatal CCTS (partial CCTS without a palatal side group and no CCTS group) were ~6–17-fold more likely to experience an unrestorable fracture than those with complete

CCTS. In cases without palatal CCTS, a full-coverage crown might be required to protect the tooth from an unrestorable fracture. This hypothesis should be evaluated by comparing the survival rates of ETT with different remaining CCTS sides and restored with DRC, and ETT restored with a crown.

In this retrospective study, maxillary anterior ETT with palatal CCTS and restored with DRC had a very high survival rate above 90%. Therefore, the remaining CCTS sides should be taken into account when considering if a crown is required for an ETT. However, that the long-term degradation of a restoration's bond to the tooth might reduce the reinforcement effect on ETT is a concern [12]. The ETT survival rate tends to gradually reduce over time. A bonded restoration should be periodically evaluated and replaced if necessary to keep maintain its reinforcement effect on the ETT.

Conclusion

In conclusion, the presence of CCTS (either complete or partial) at the palatal side increased the survival rate from unrestorable fracture in maxillary anterior ETT restored with DRC.

Acknowledgements

The authors are grateful to Assistant Prof. Dr. Chulaluk Komoltri and Dr. Sittichoke Osiri for their assistance in statistical analyses.

Funding resources: Residency training research scholarship (Faculty of Dentistry, Mahidol University).

Conflict of Interest: The authors deny any conflicts of interest related to this study.

References

1. Landys Boren D, Jonasson P, Kvist T. Long-term survival of endodontically treated teeth at a public dental specialist clinic. *J Endod* 2015; 41: 176-81.
2. Sedgley CM, Messer HH. Are endodontically treated teeth more brittle? *J Endod* 1992; 18: 332-35.
3. Faria AC, Rodrigues RC, de Almeida Antunes RP, de Mattos Mda G, Ribeiro RF. Endodontically treated teeth: characteristics and considerations to restore them. *J Prosthodont Res* 2011; 55: 69-74.
4. Dietschi D, Duc O, Krejci I, Sadan A. Biomechanical considerations for the restoration of endodontically treated teeth: a systematic review of the literature, Part II (Evaluation of fatigue behavior, interfaces, and in vivo studies). *Quintessence Int* 2008; 39: 117-29.
5. Ng CC, Dumbrigue HB, Al-Bayat MI, Griggs JA, Wakefield CW. Influence of remaining coronal tooth structure location on the fracture resistance of restored endodontically treated anterior teeth. *J Prosthet Dent* 2006; 95: 290-96.
6. Muangamphan P, Sattapan B, Kukiattrakoon B, Thammasitboon K. The effect of incomplete crown ferrules on fracture resistance and failure modes of endodontically treated maxillary incisors restored with quartz fiber post, composite core, and crowns. *J Conserv Dent* 2015; 18: 187-91.
7. Sorensen JA, Martinoff JT. Intracoronary reinforcement and coronal coverage: a study of endodontically treated teeth. *J Prosthet Dent* 1984; 51: 780-84.
8. Dammaschke T, Nykiel K, Sagheri D, Schafer E. Influence of coronal restorations on the fracture resistance of root canal-treated premolar and molar teeth: a retrospective study. *Aus Endod J* 2013; 39: 48-56.
9. Juloski J, Radovic I, Goracci C, Vulicevic ZR, Ferrari M. Ferrule effect: a literature review. *J Endod* 2012; 38: 11-19.
10. Torbjørner A, Fransson B. Biomechanical aspects of prosthetic treatment of structurally compromised teeth. *Int J Prosthodont* 2004; 17: 135-41.
11. Dikbas I, Tanalp J, Ozel E, Koksall T, Ersoy M. Evaluation of the effect of different ferrule designs on the fracture resistance of endodontically treated maxillary central incisors incorporating fiber posts, composite cores and crown restorations. *J Contemp Dent Pract* 2007; 8: 62-69.
12. Hashimoto M, Ohno H, Kaga M, Endo K, Sano H, Oguchi H. In vivo degradation of resin-dentin bonds in humans over 1 to 3 years. *J Dent Res* 2000; 79: 1385-91.